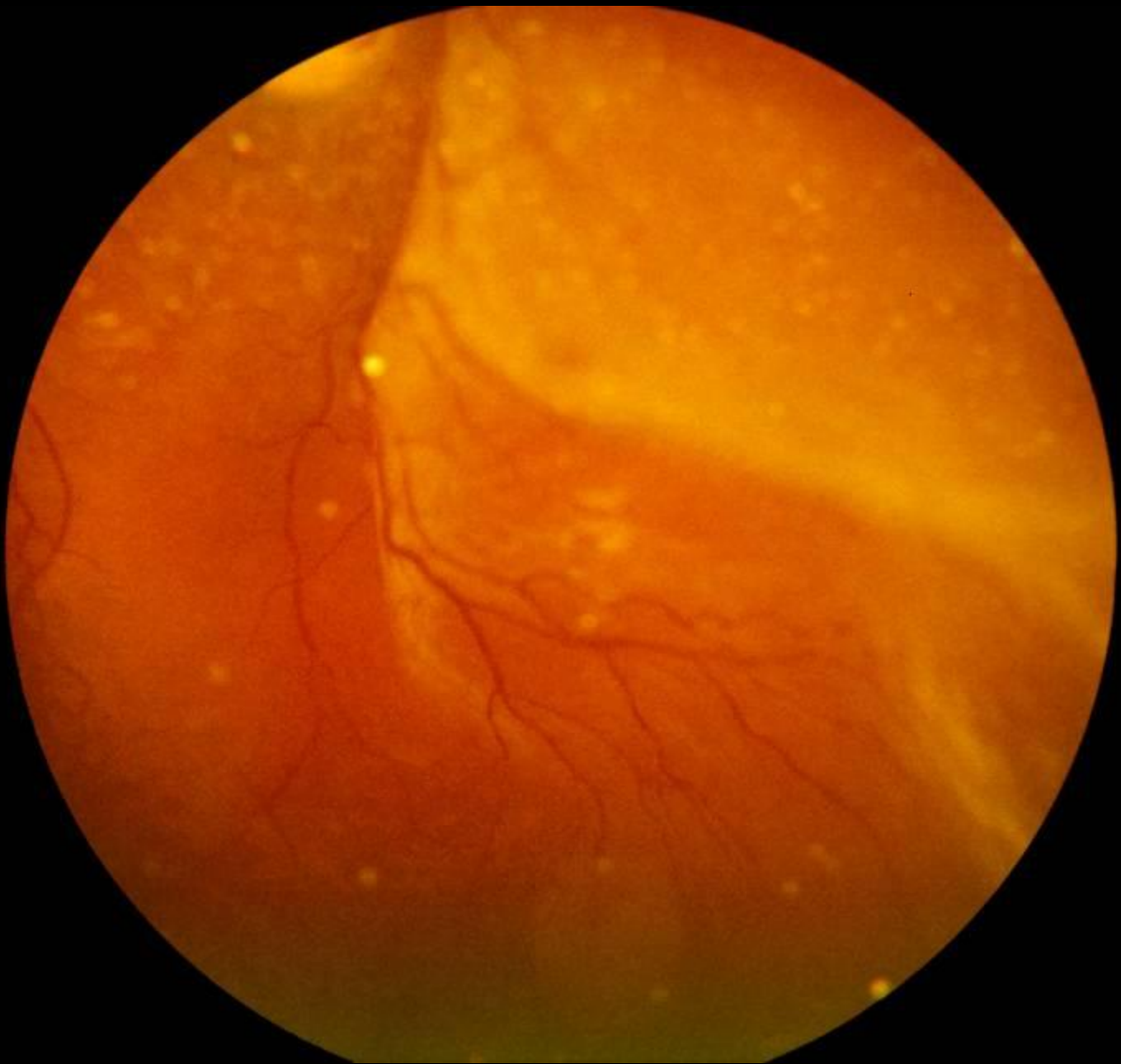

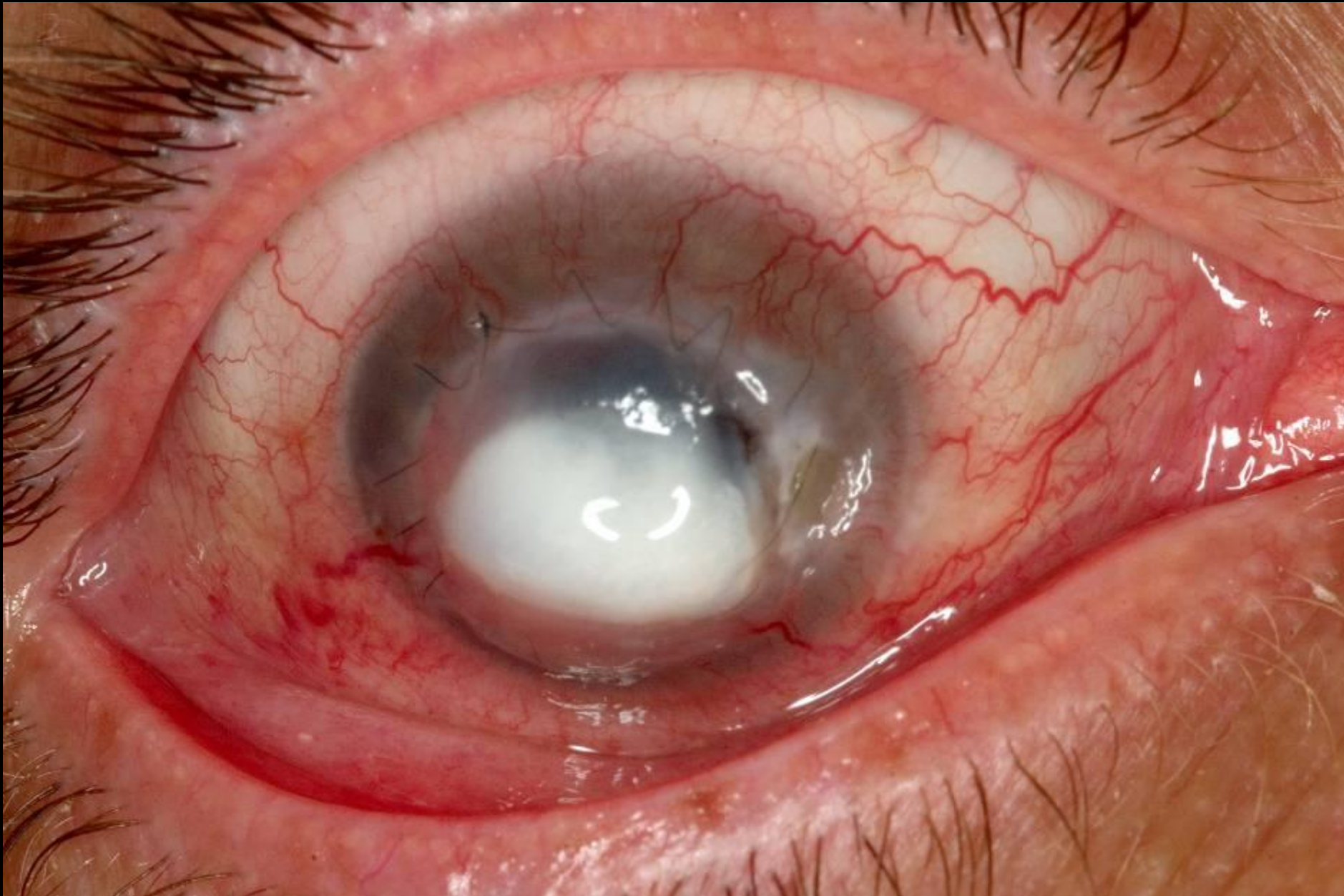
DE ÁOK Szemészeti Tanszék

Gyakorlati vizsga képanyaga

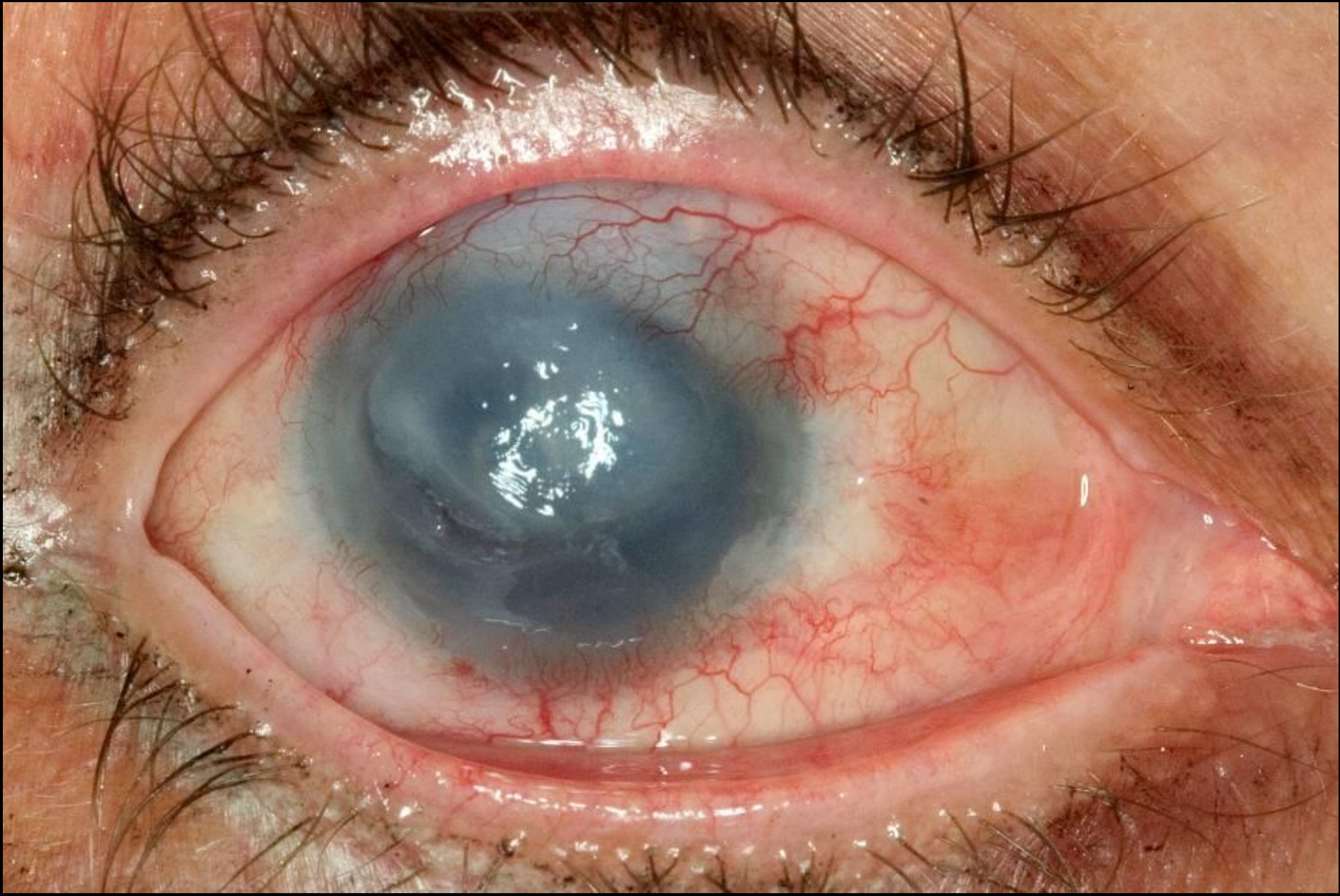



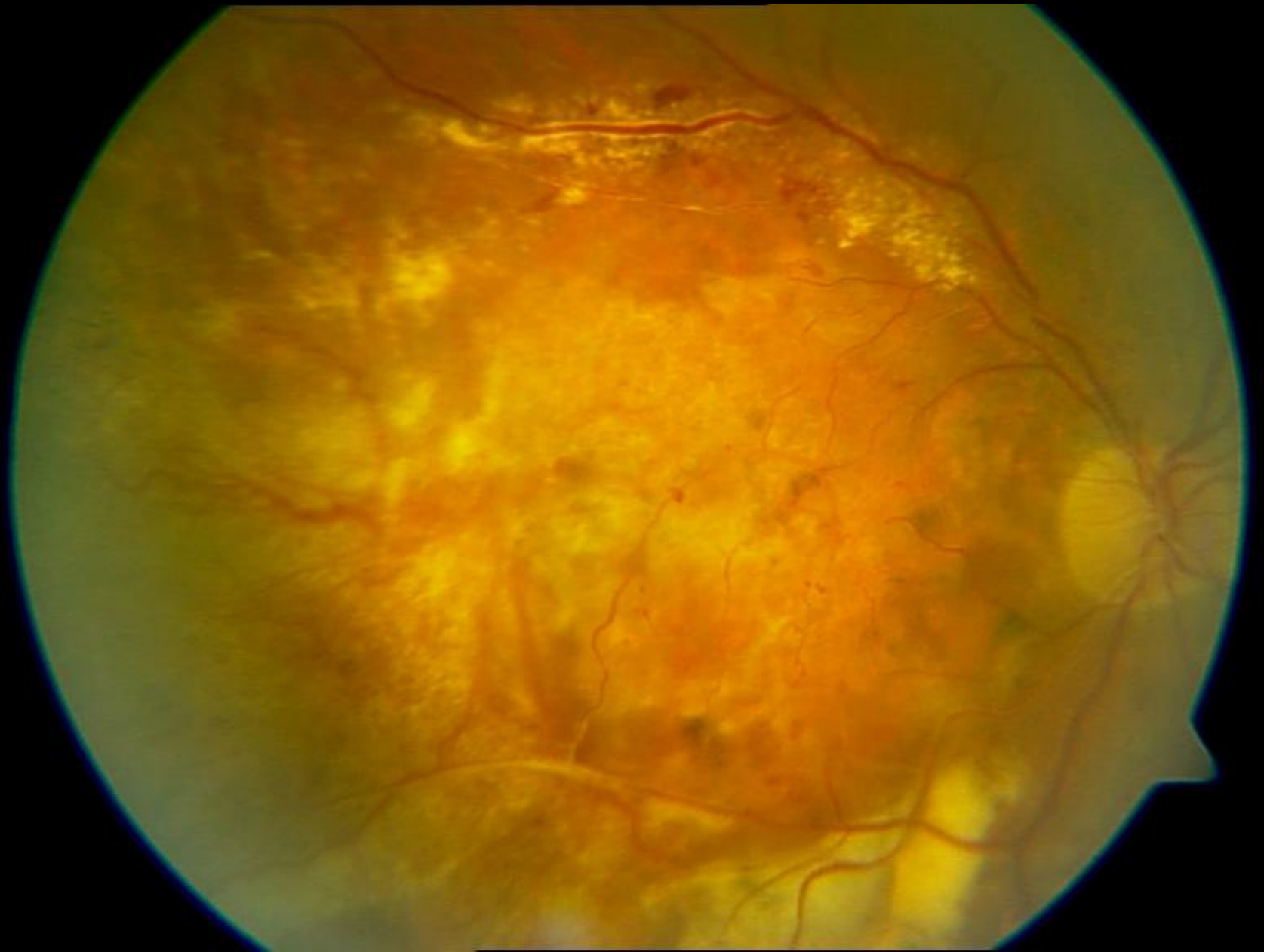ablatio retinae



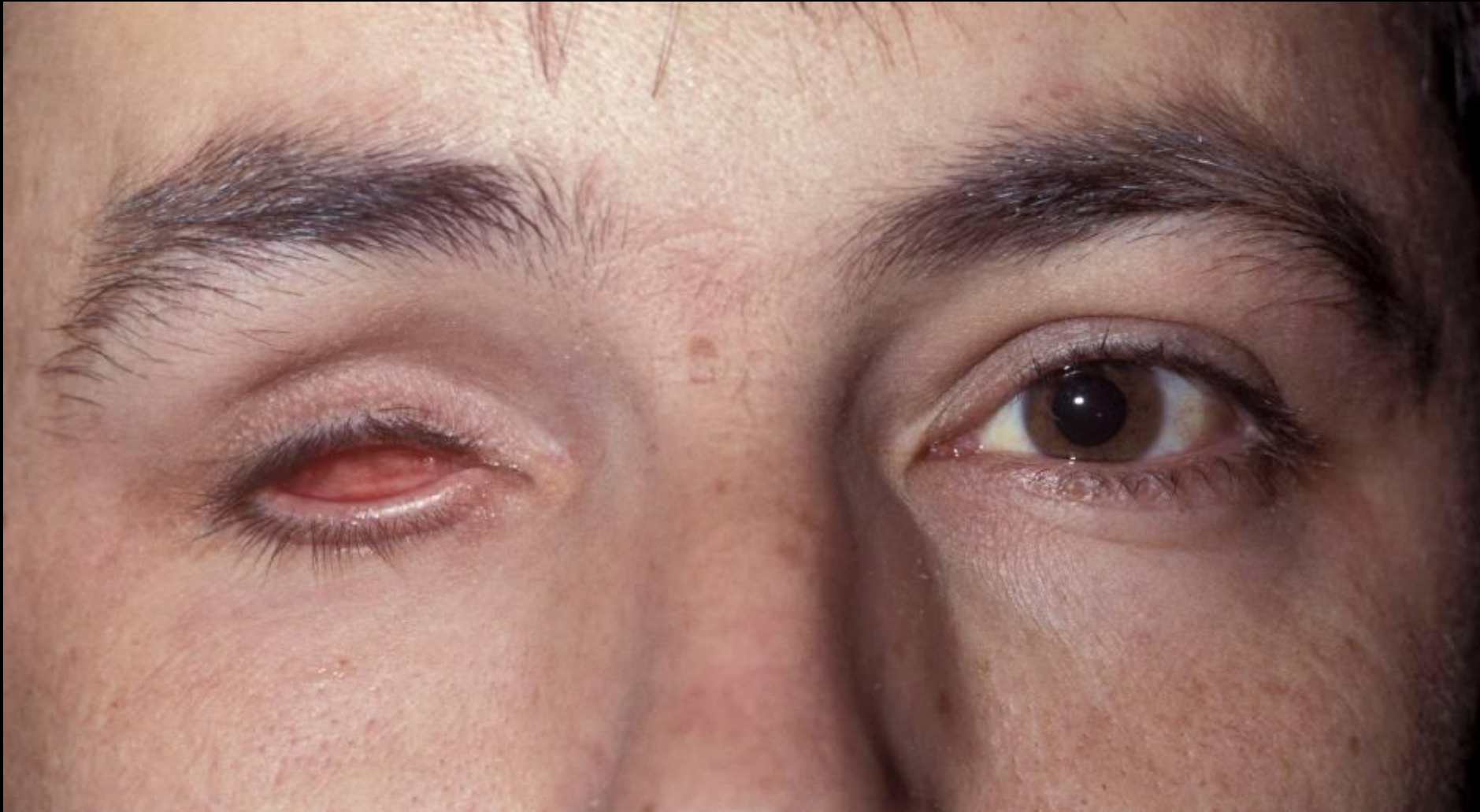abscessus corneae



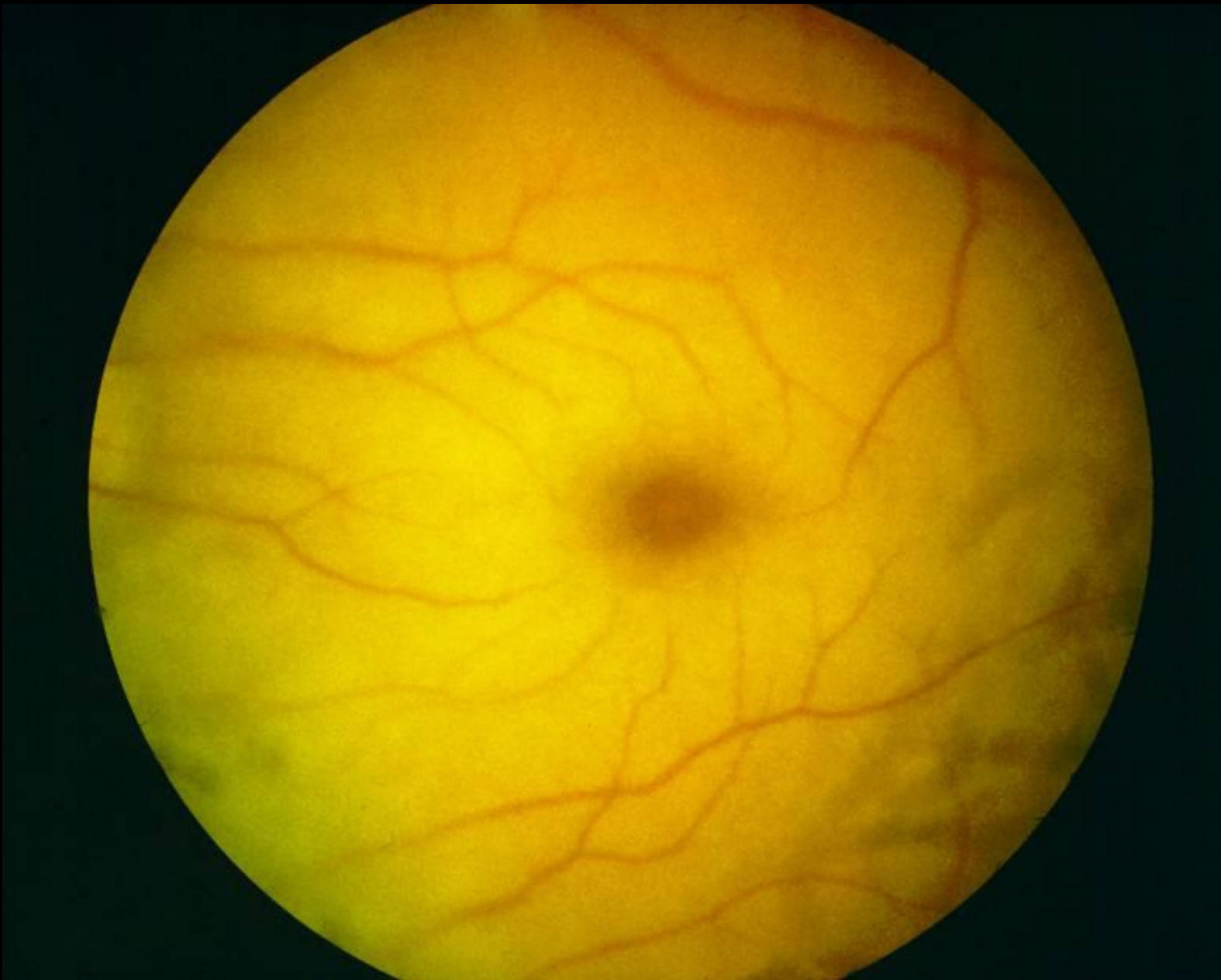keratitis (valószínűleg Acanthamoeba talaján kialakult)



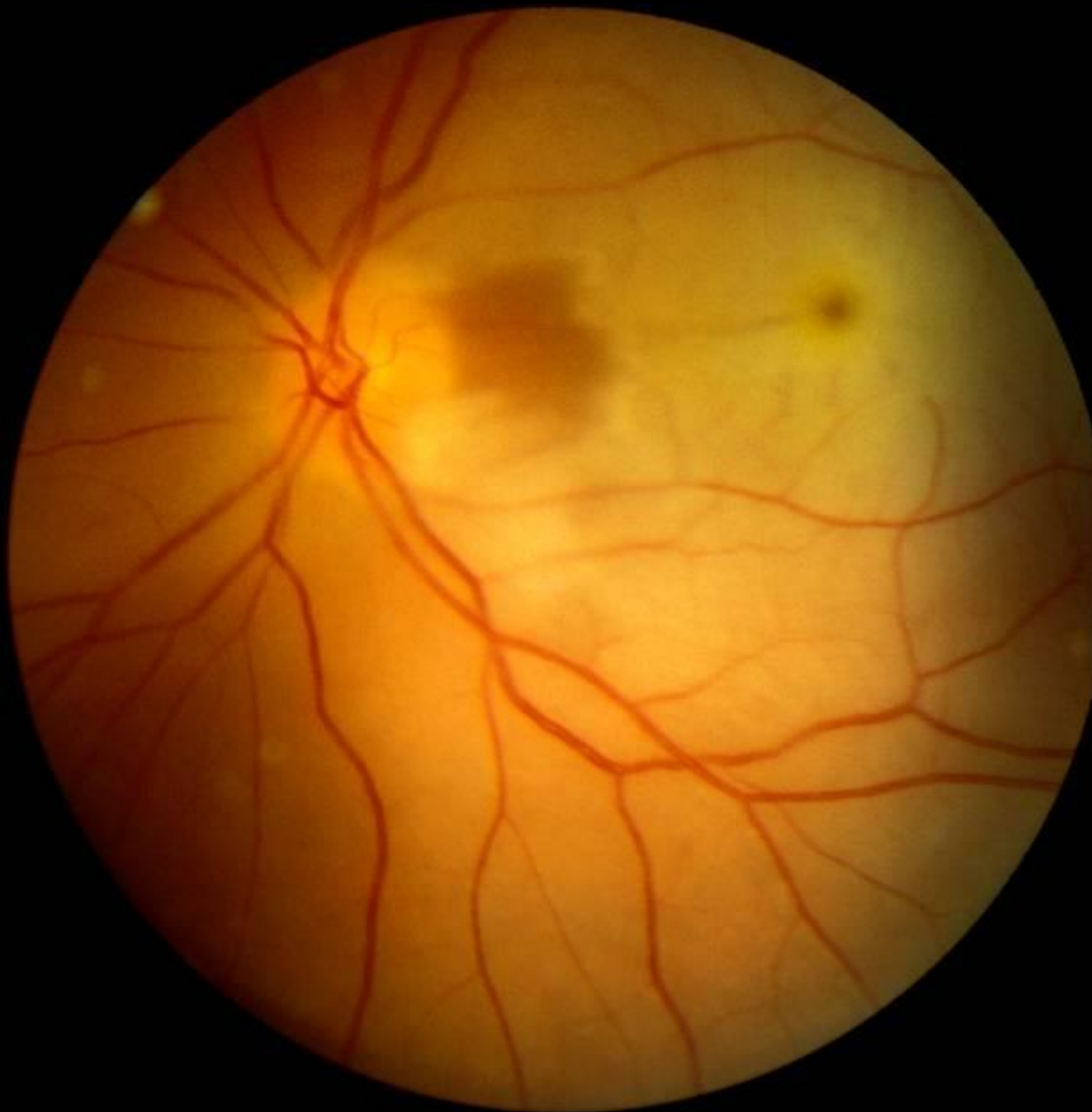
degeneratio maculae luteae exsudativa



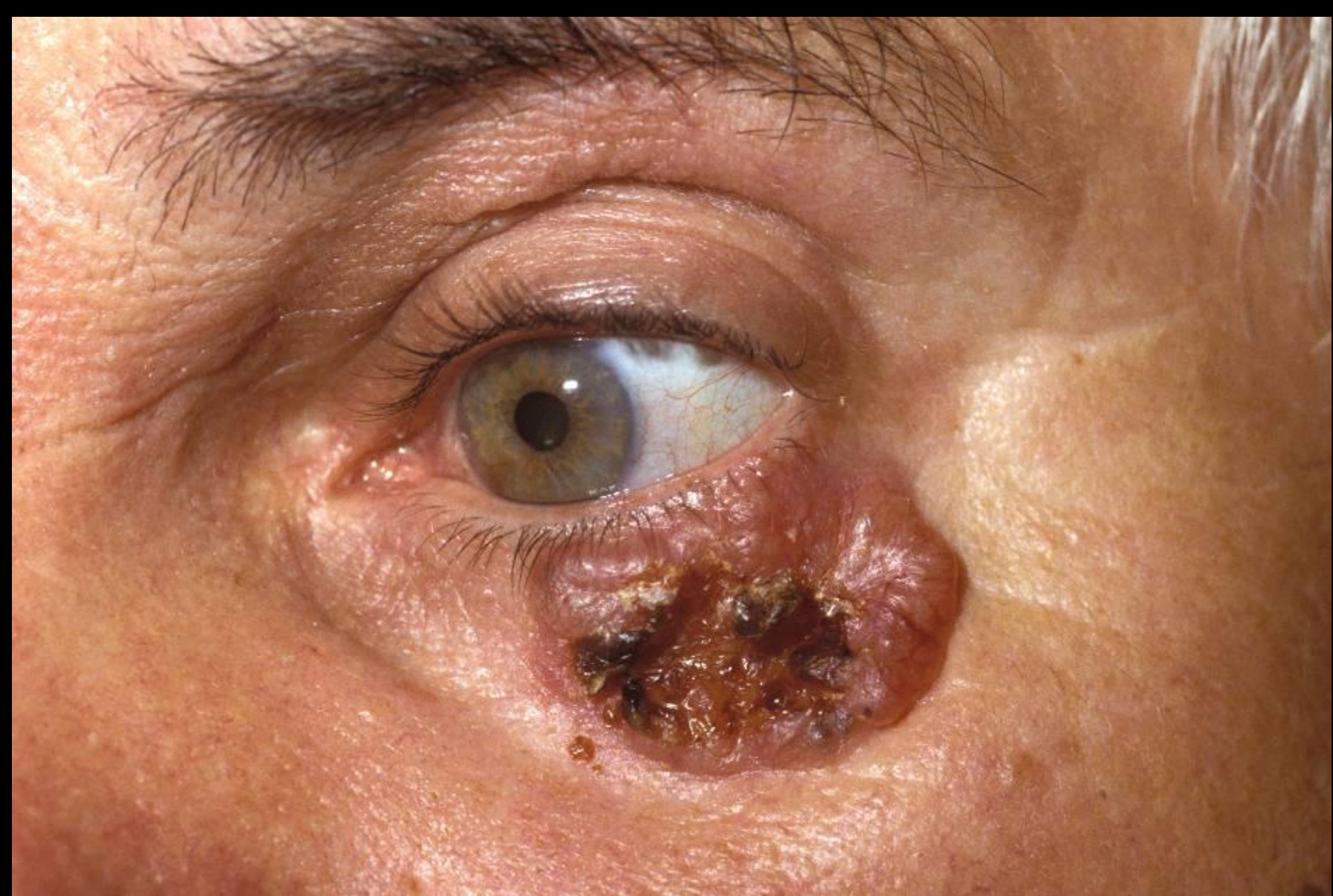anophthalmus



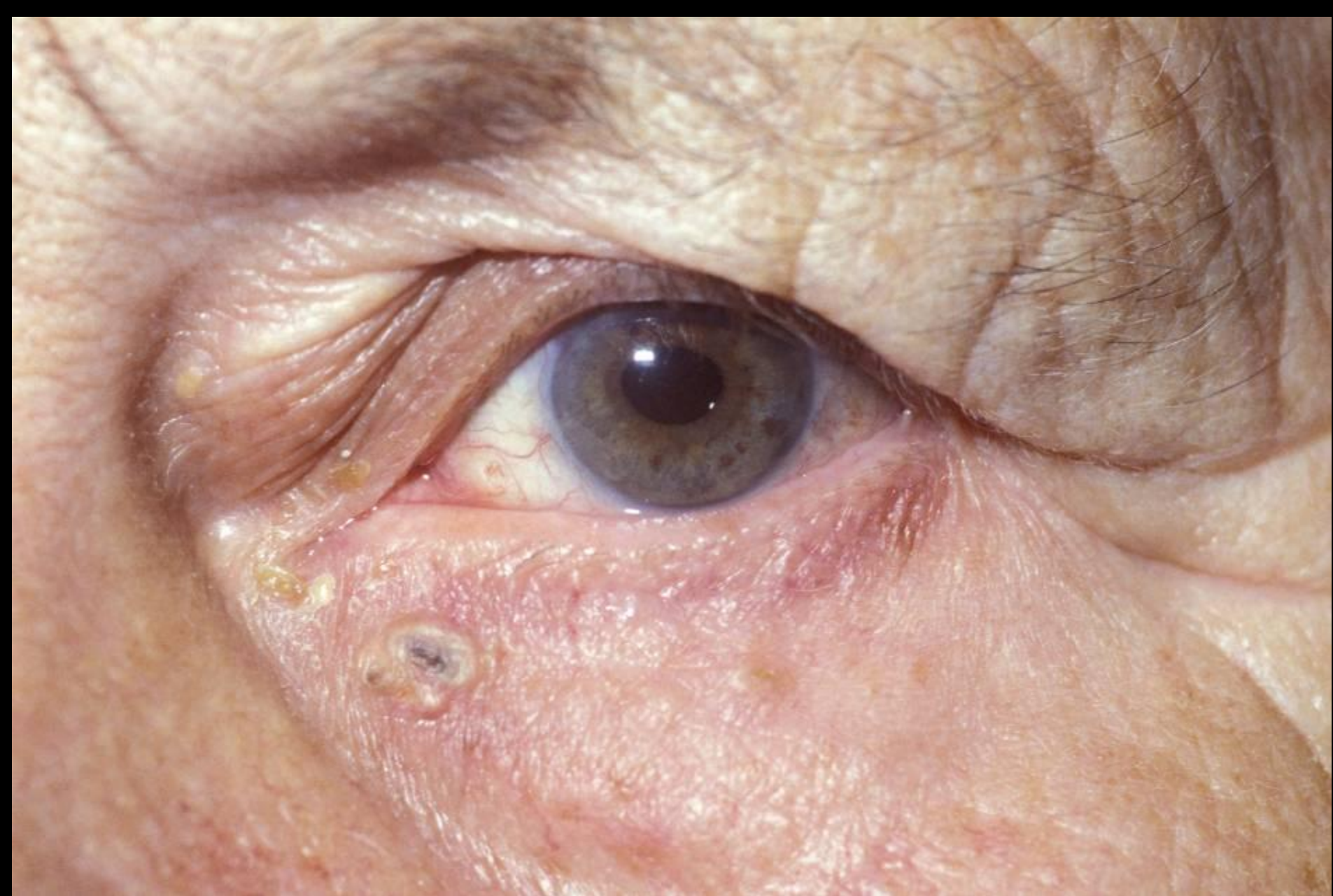occlusio arteriae centralis retinae



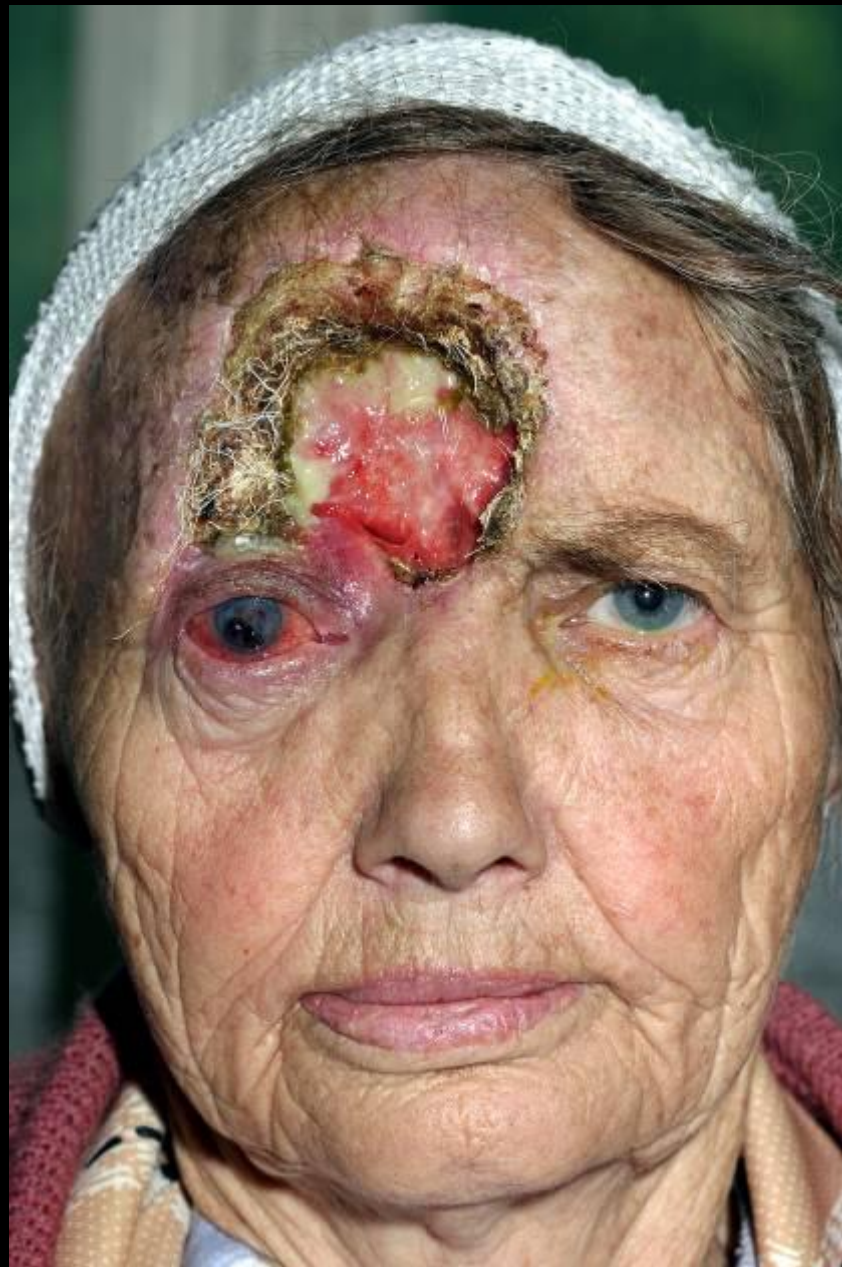macula területét érintő artériás occlusio



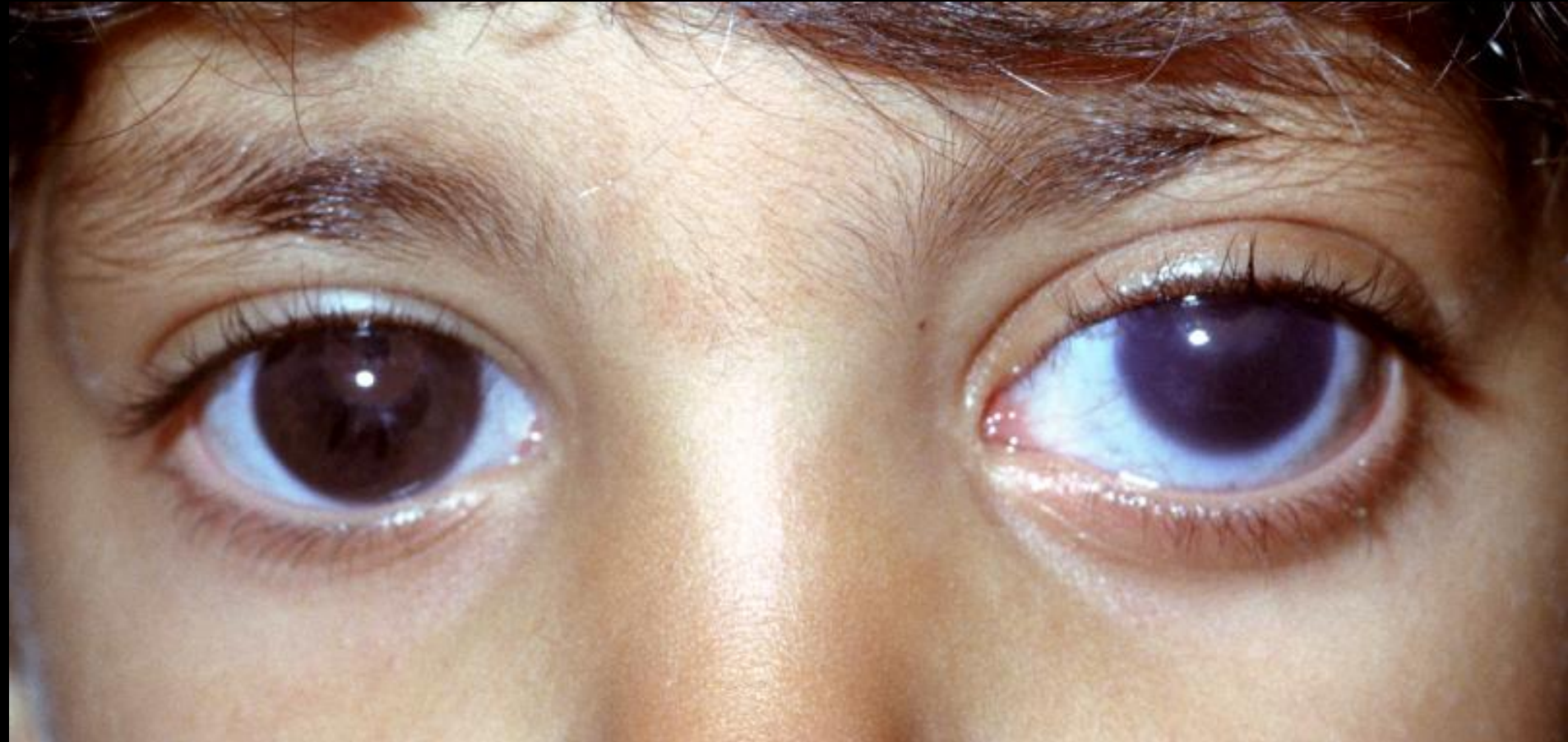basalioma palpebrae inferioris



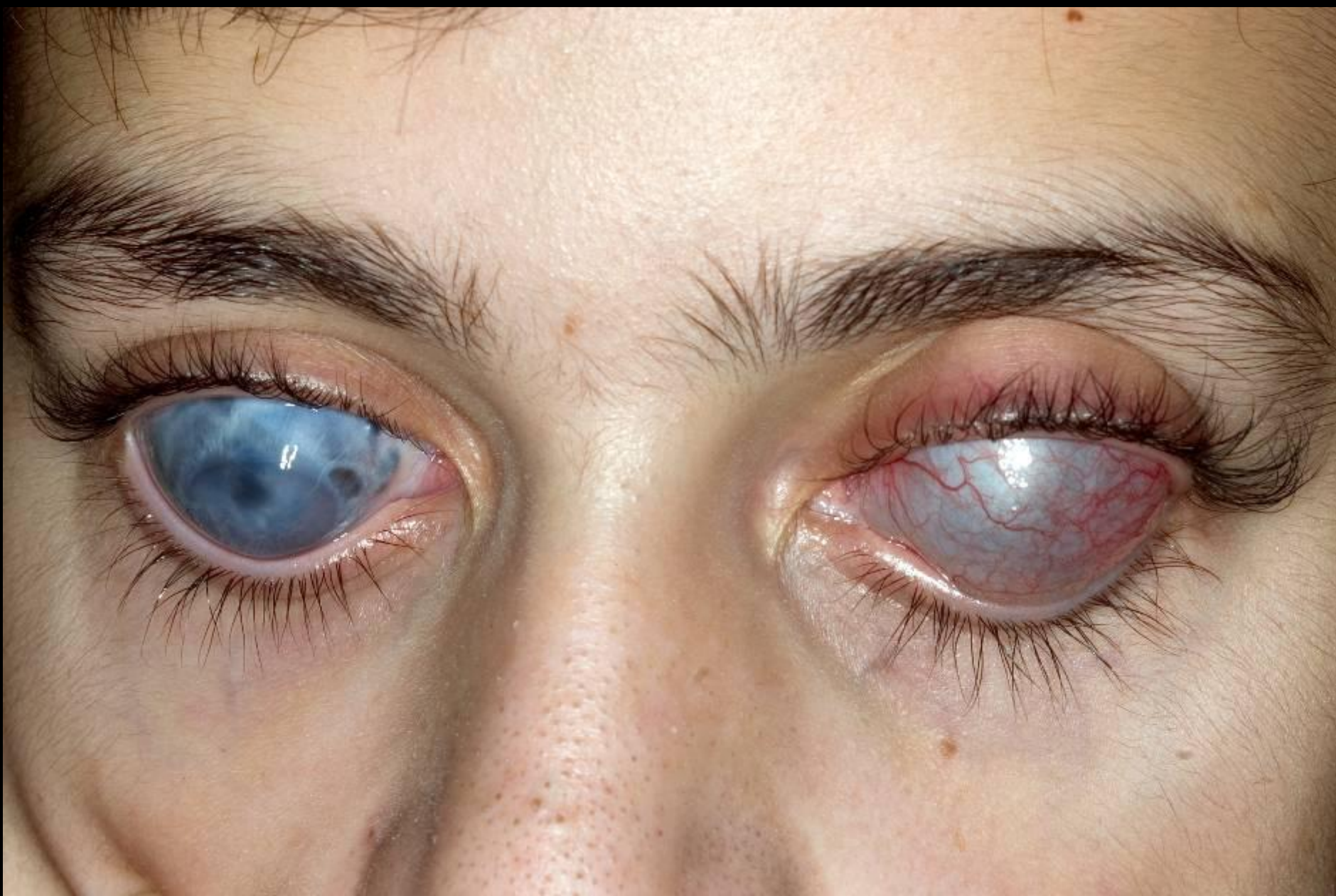basalioma palpebrae inferioris



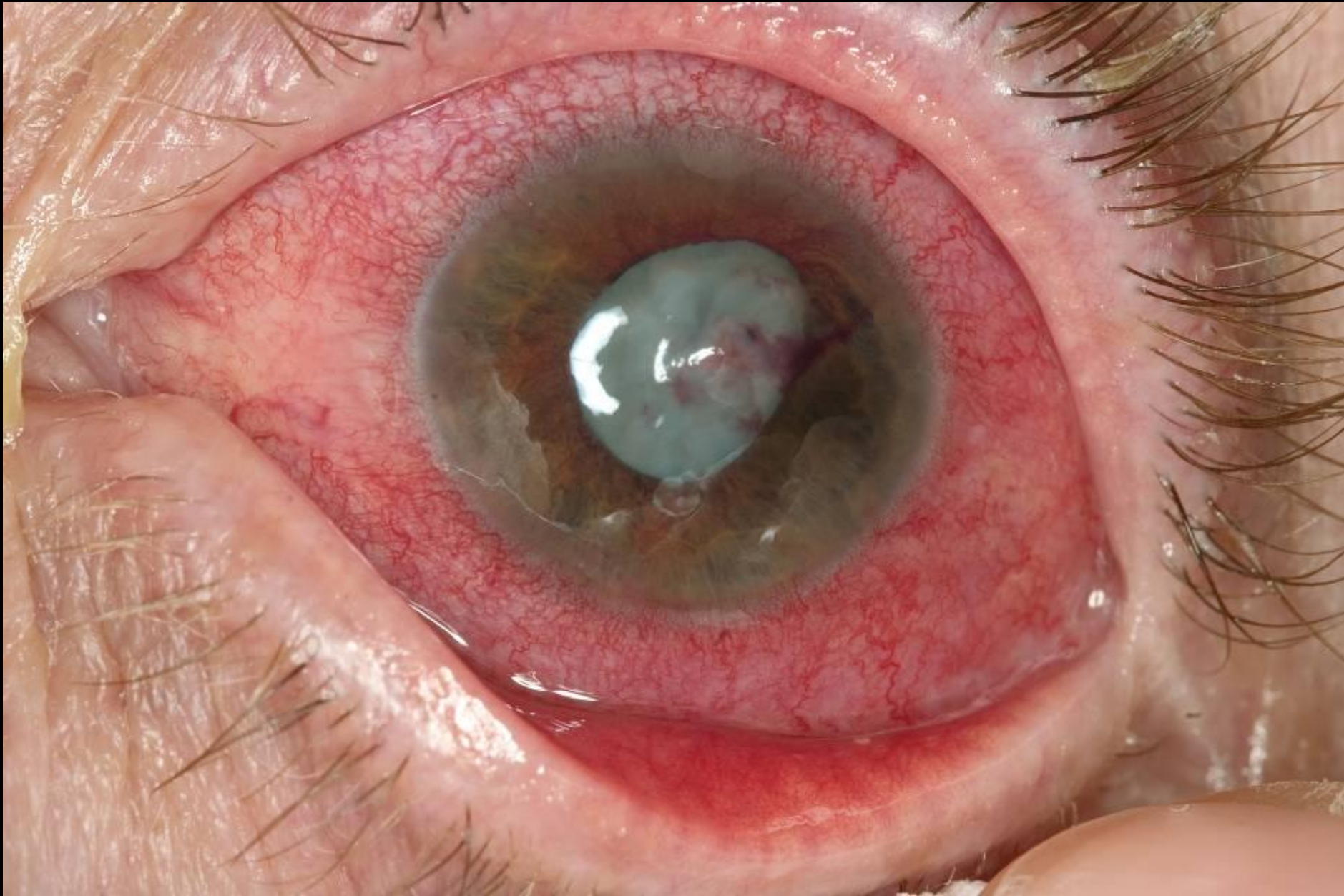
basalioma



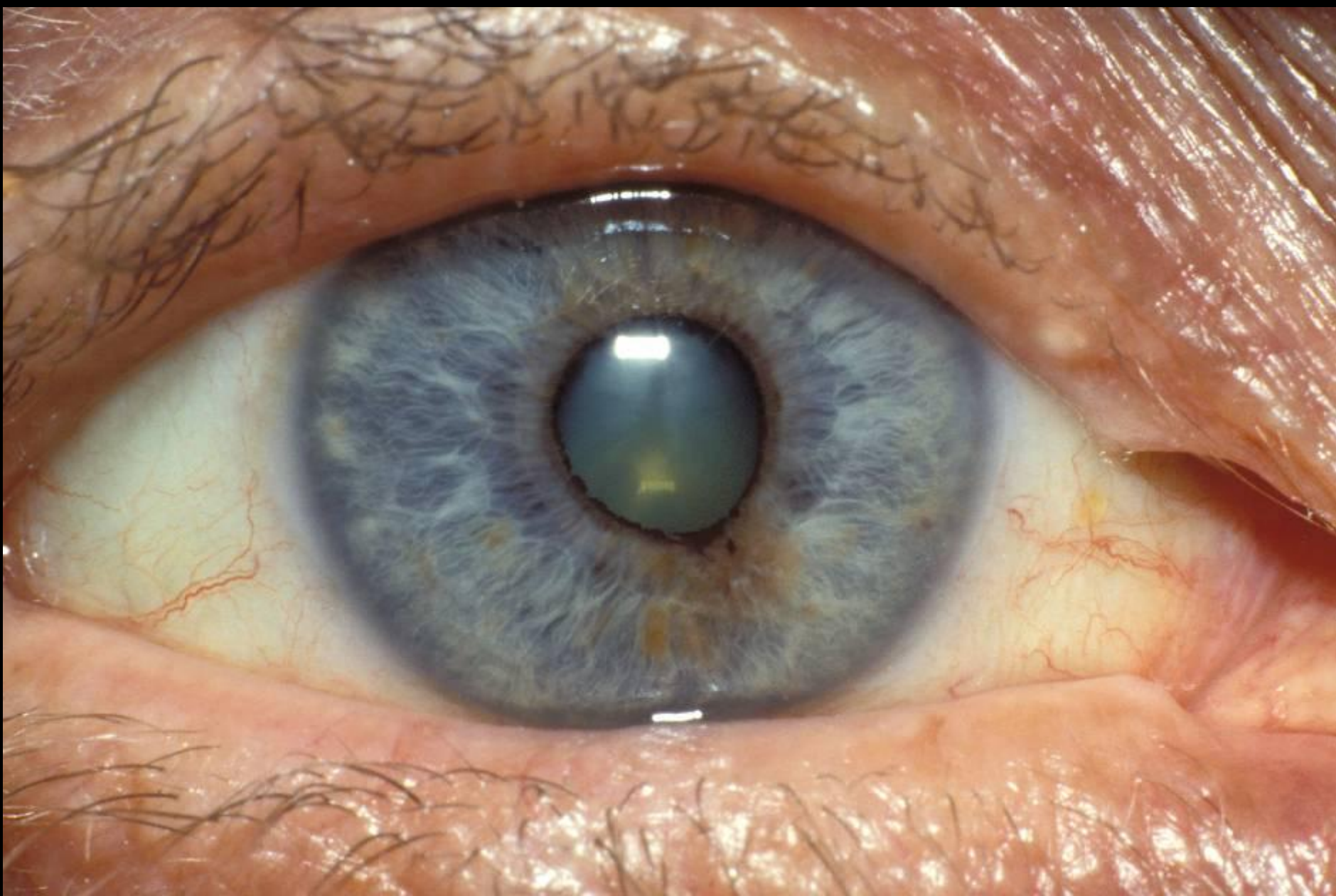
buphthalmus



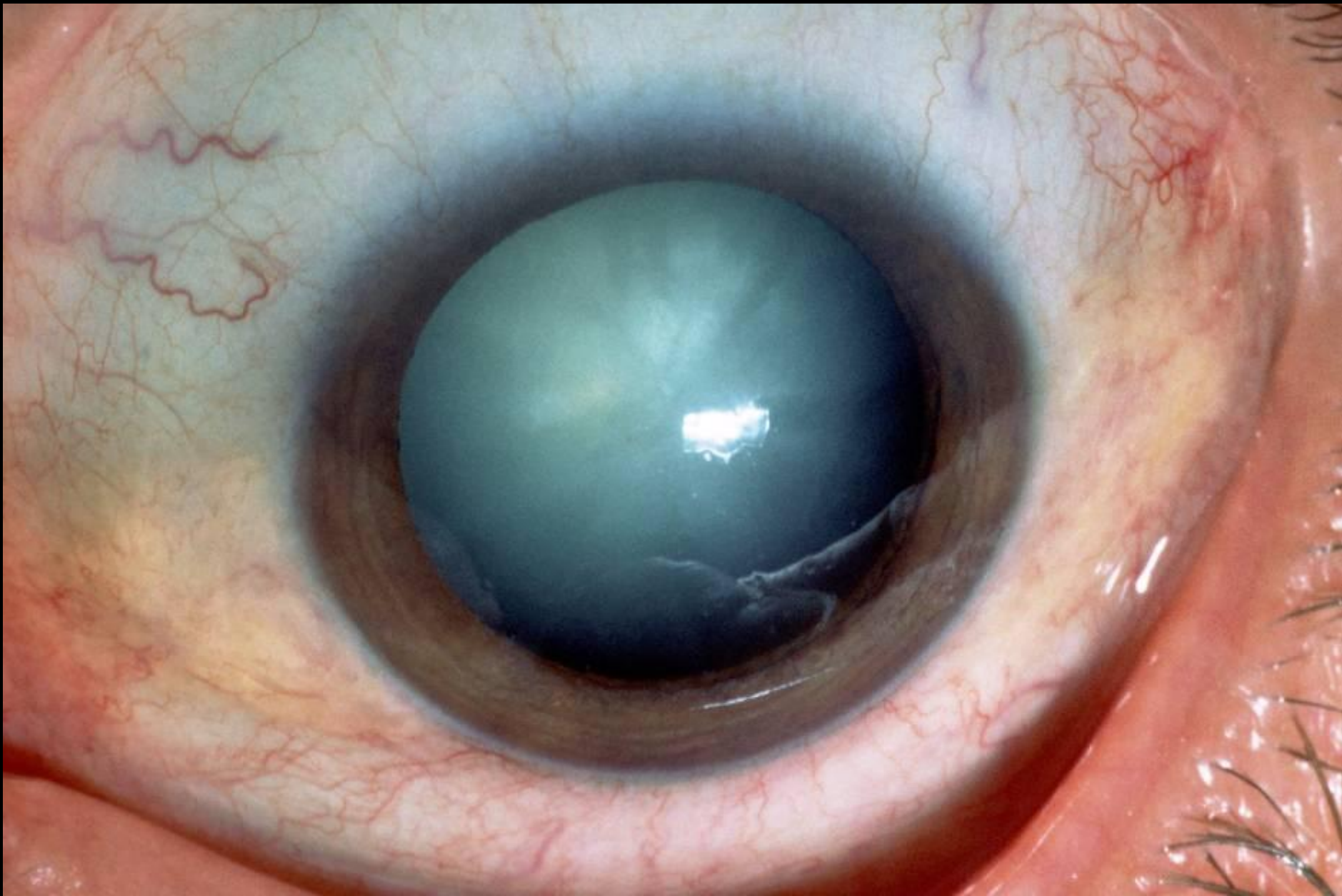
buphthalmus (végállapot)



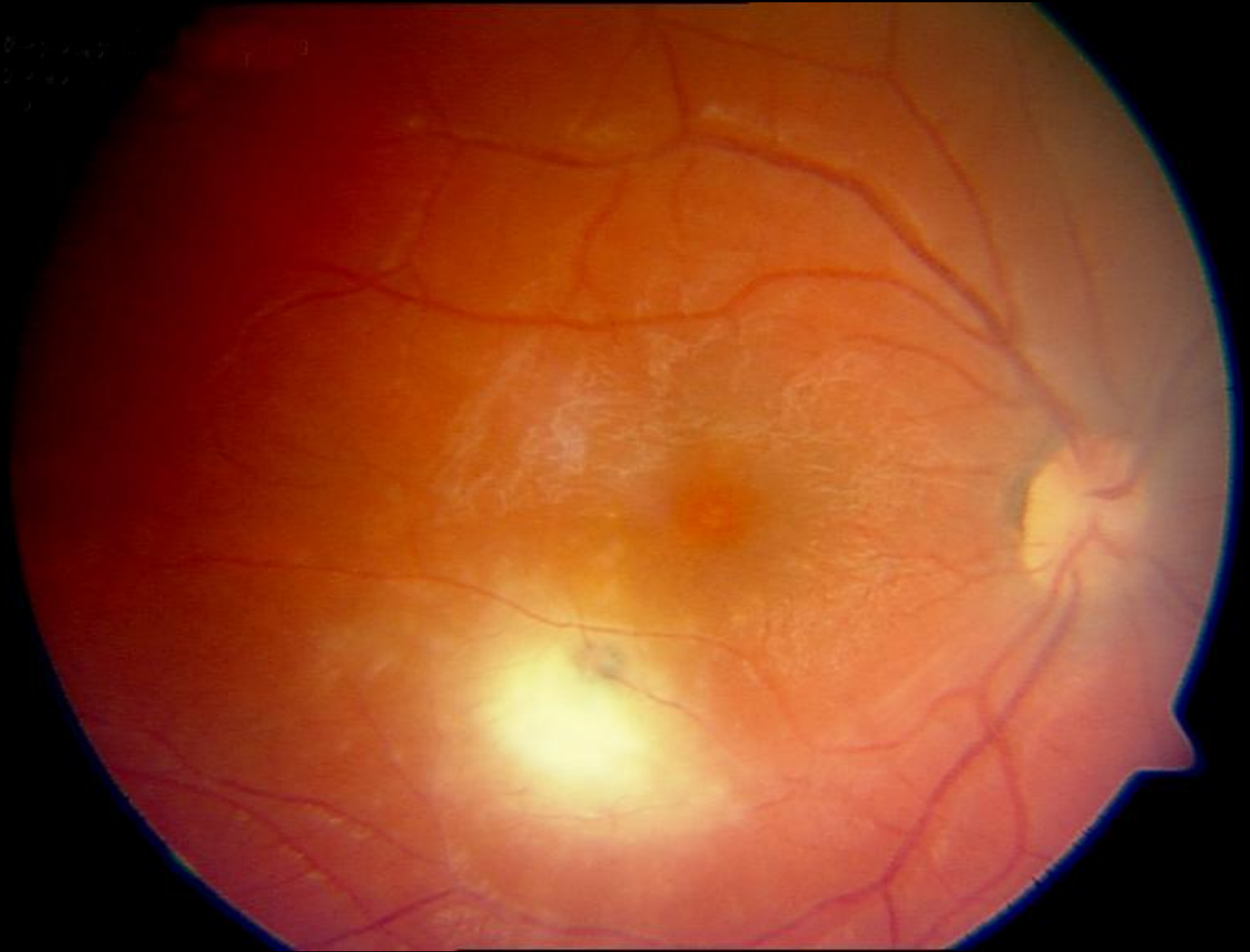
cataracta traumatica et rubeosis iridis



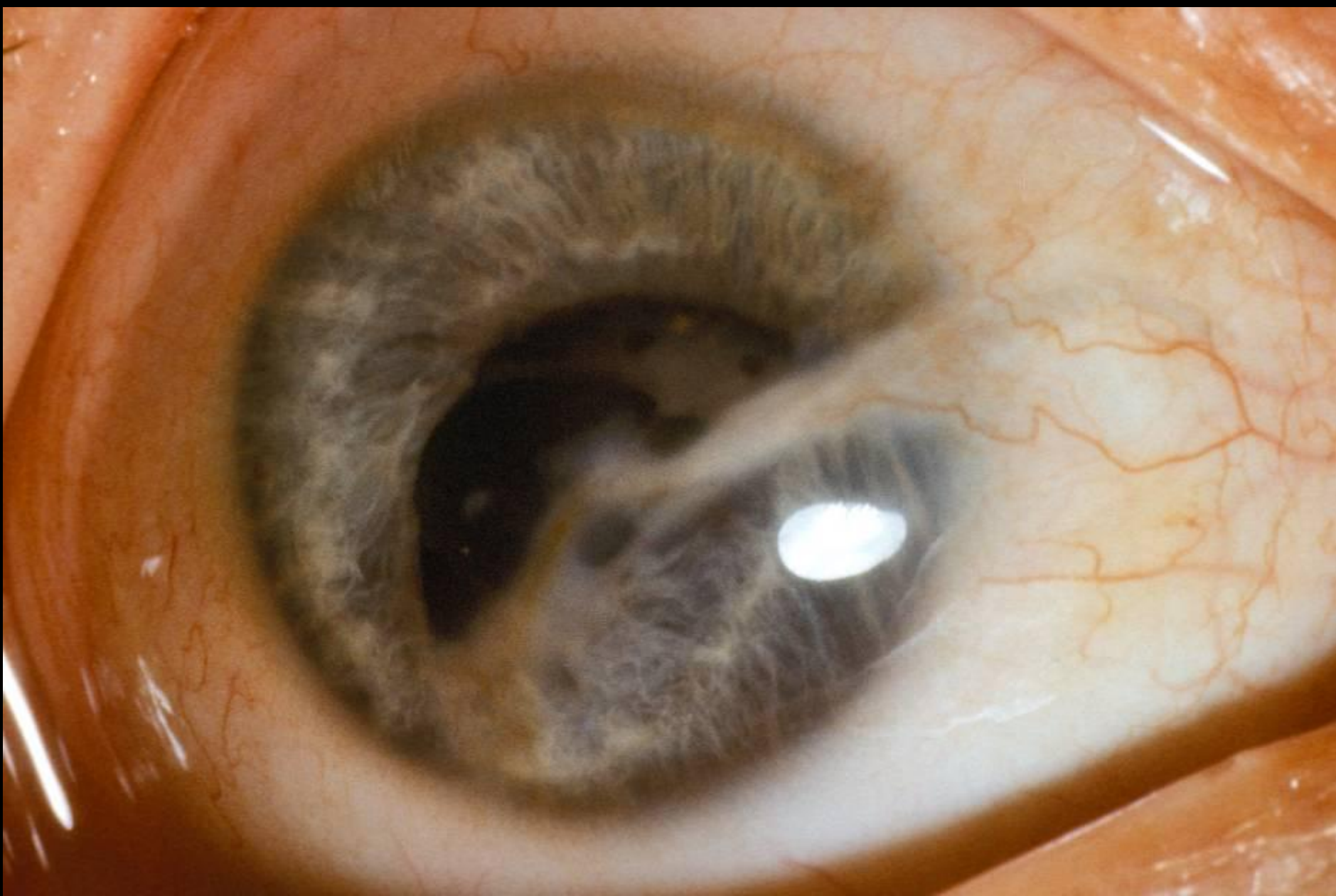
cataracta fere totalis, szűk pupilla mellett



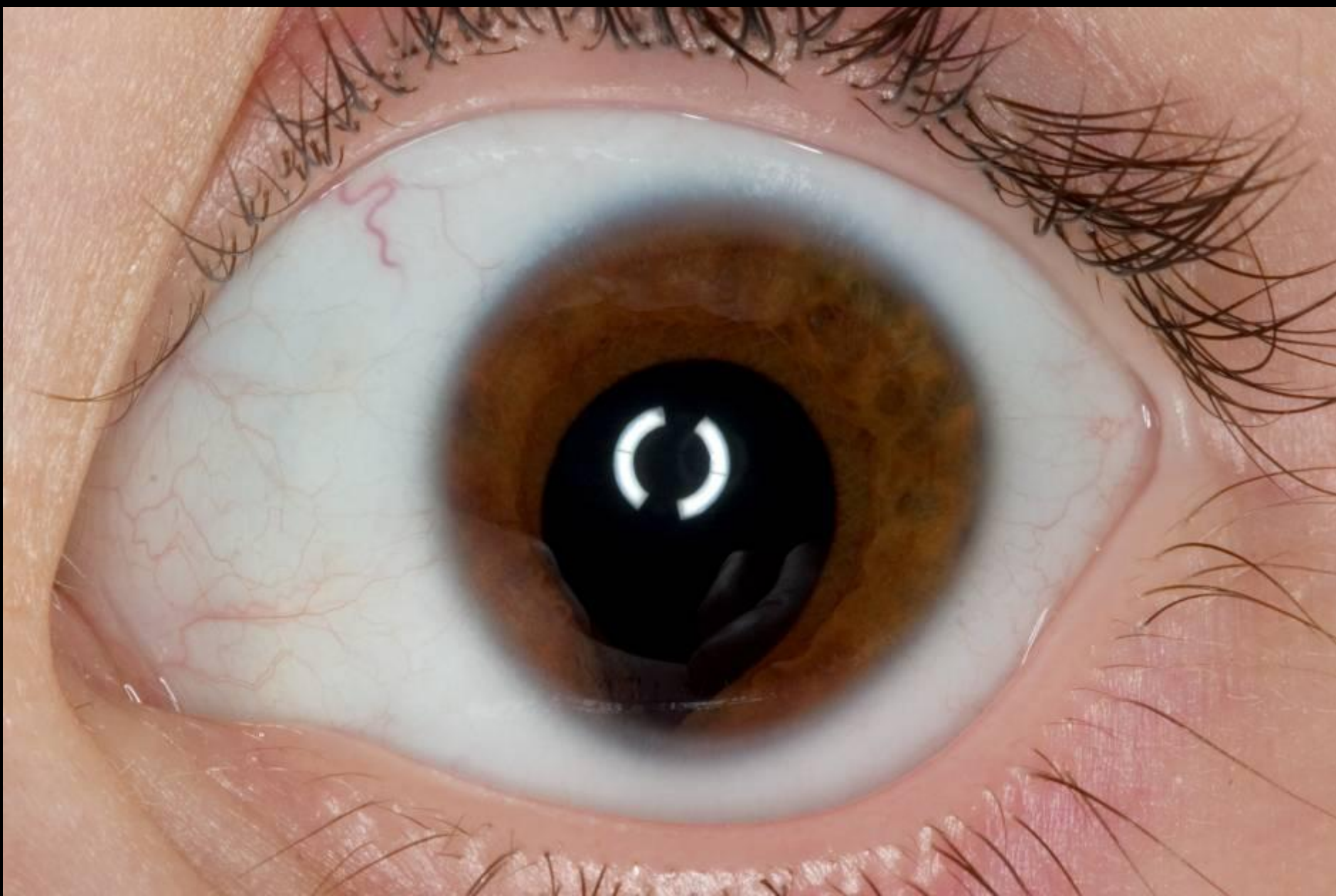cataracta totalis tág pupilla mellett



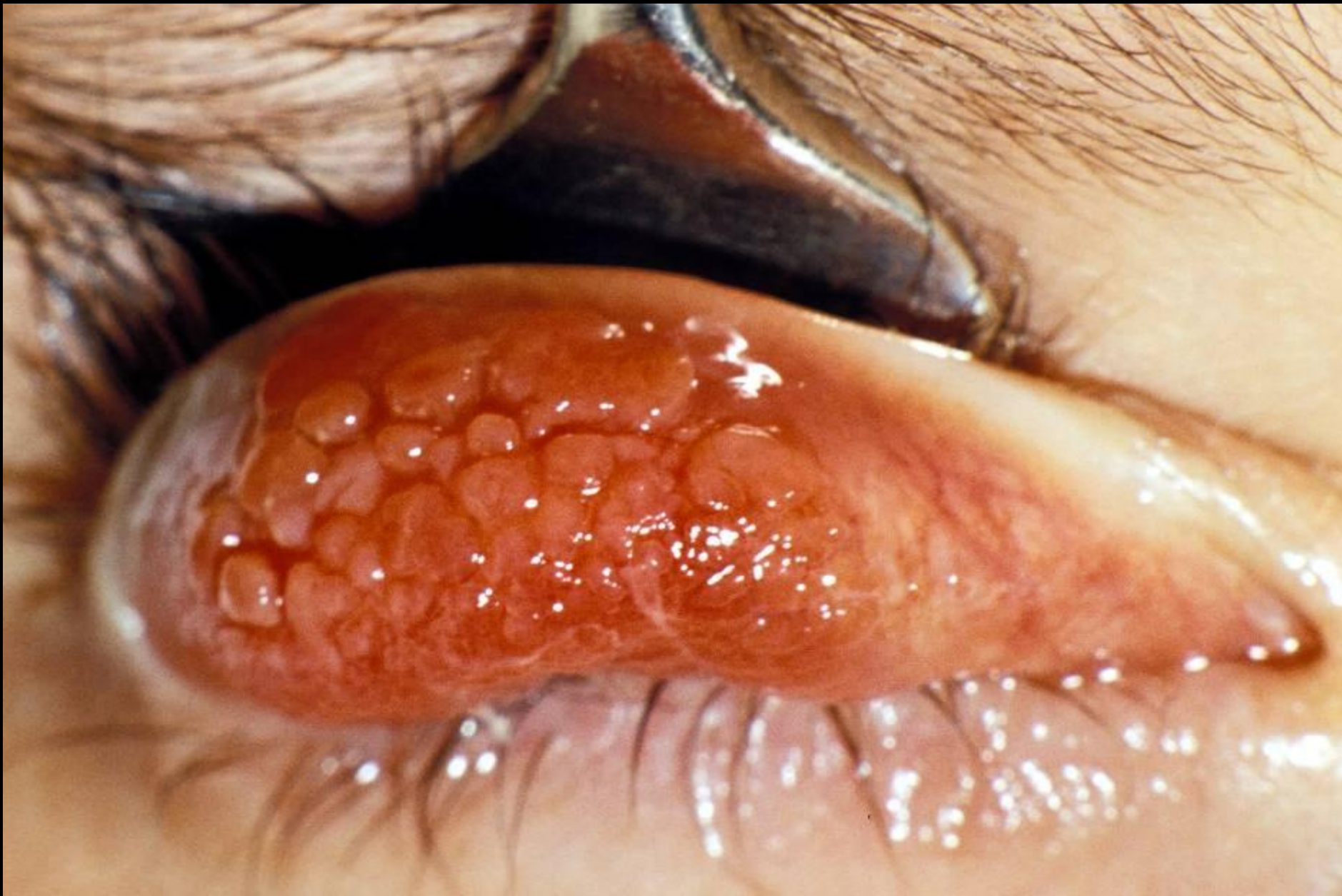chorioretinitis focalis (friss)



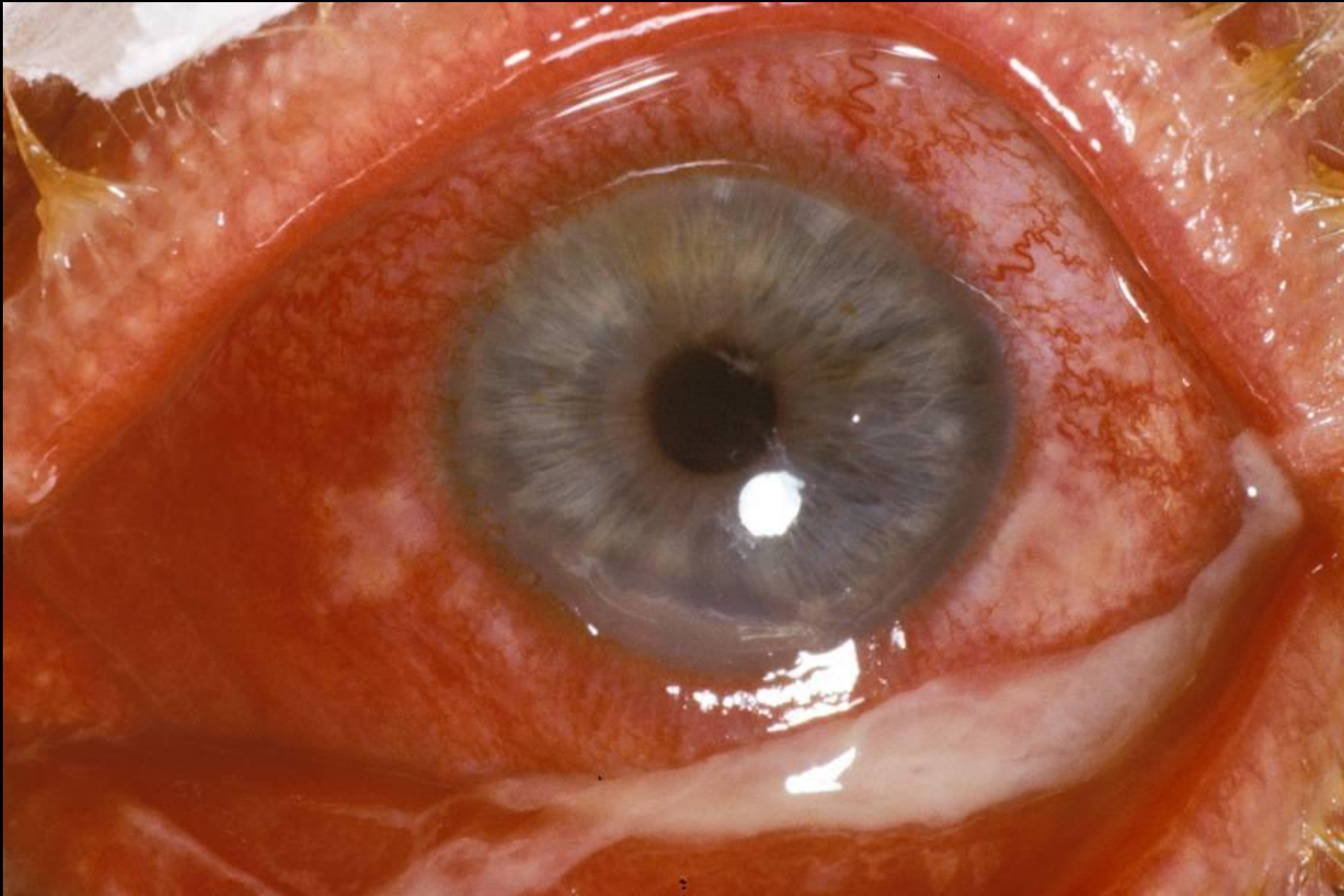
cicatrix corneae



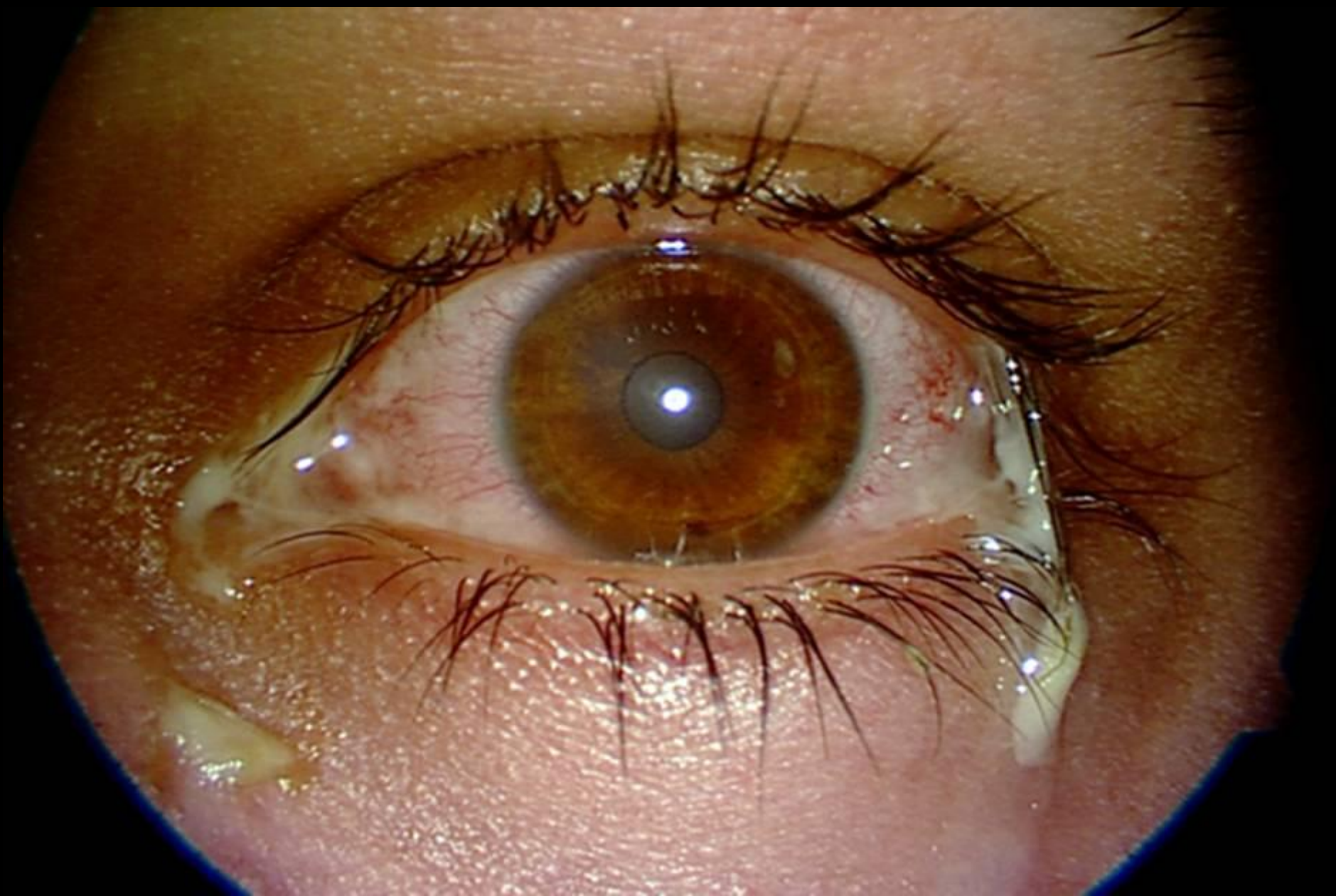
coloboma iridis congenitalis



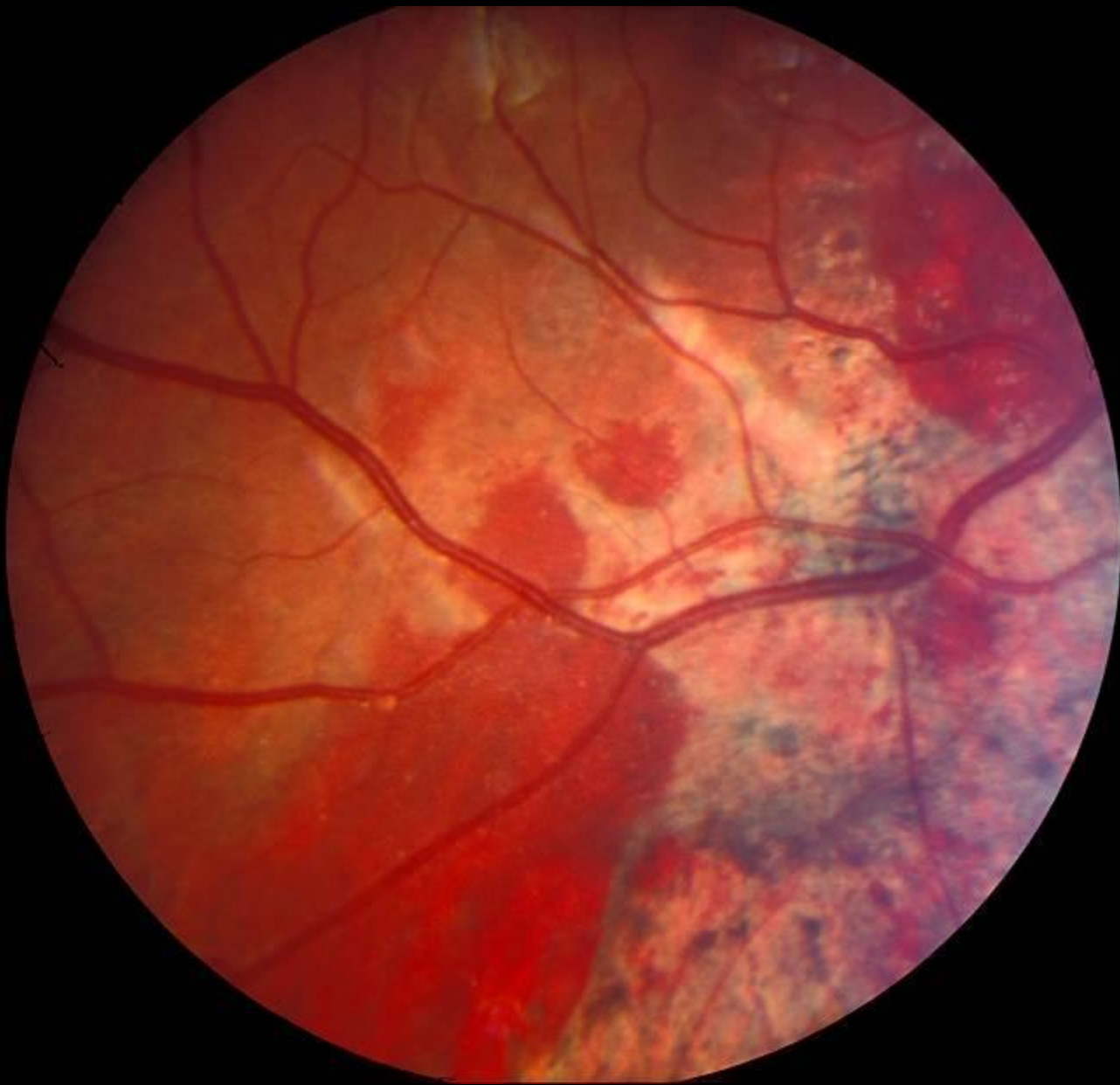
conjunctivitis vernalis



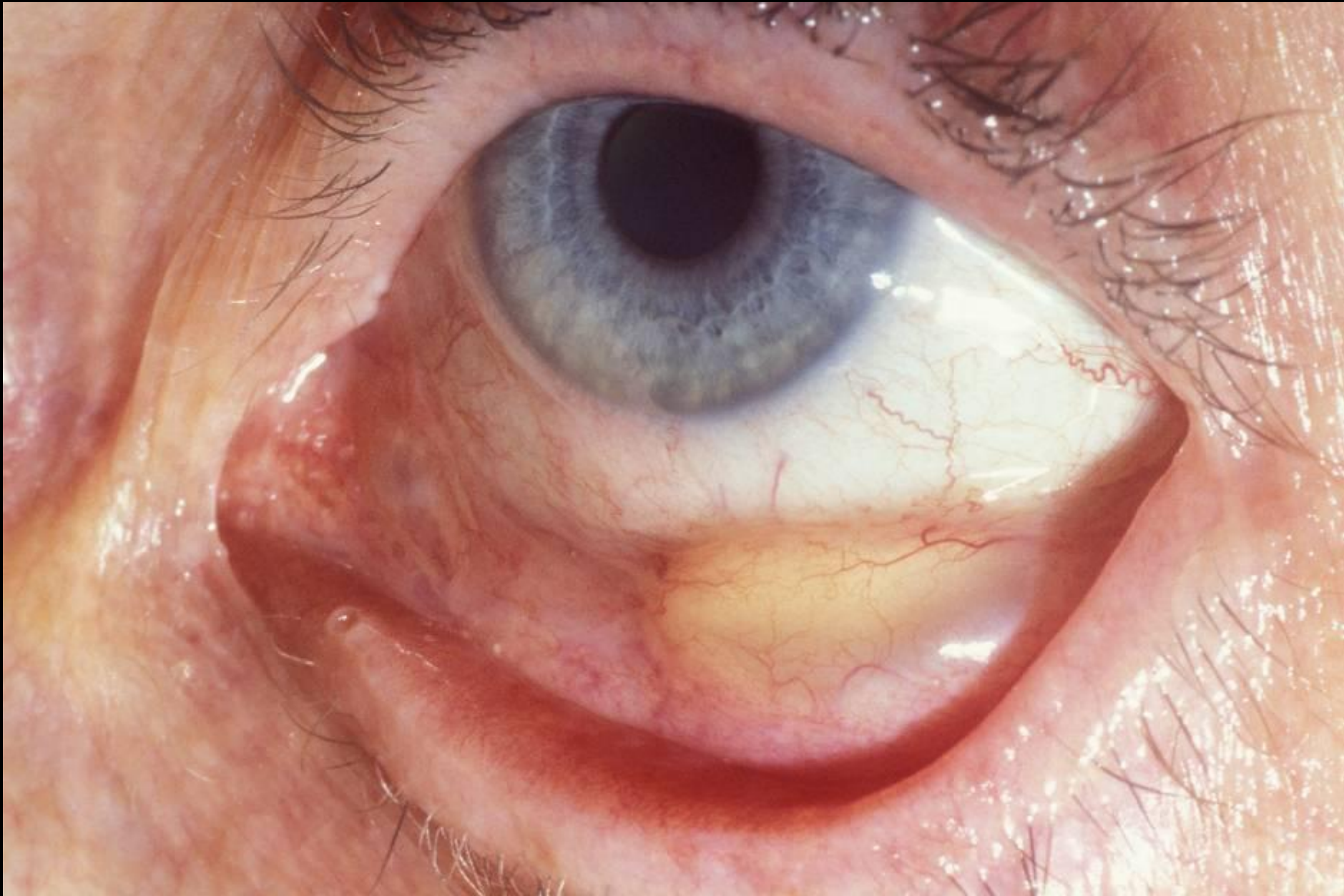conjunctivitis bacterialis acuta



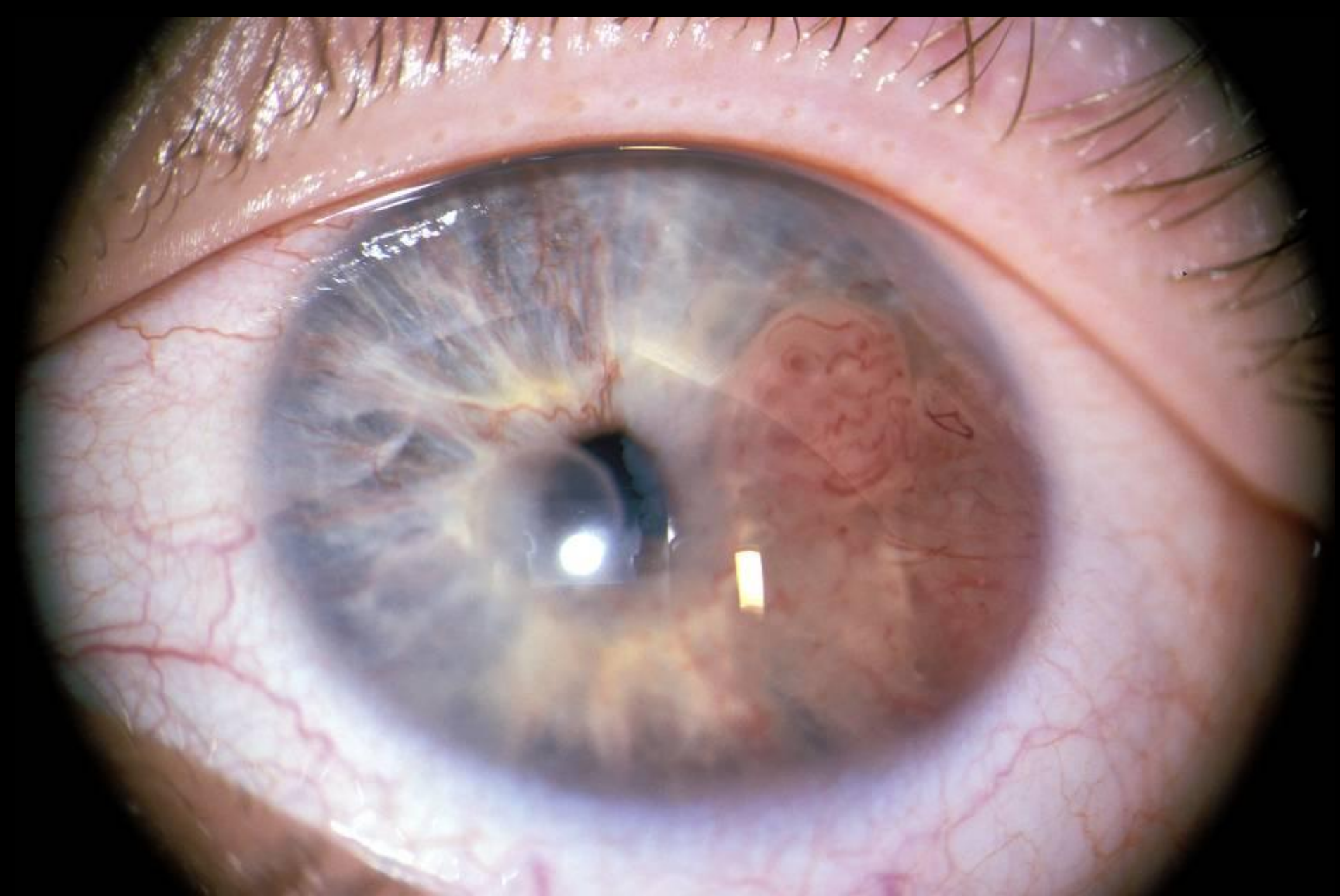
conjunctivitis bacterialis acuta



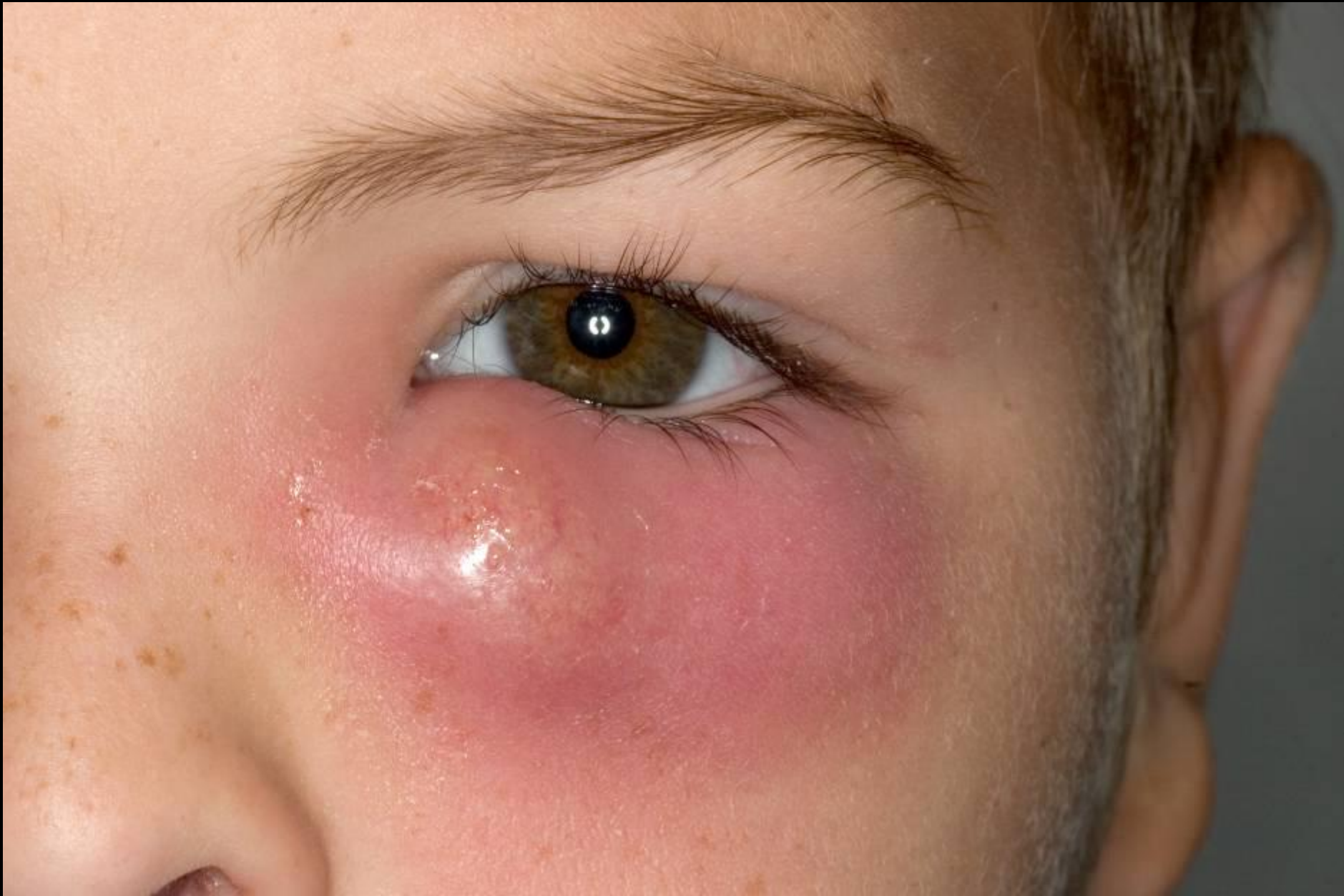status post contusionem bulbi et haemorrhagia retinae



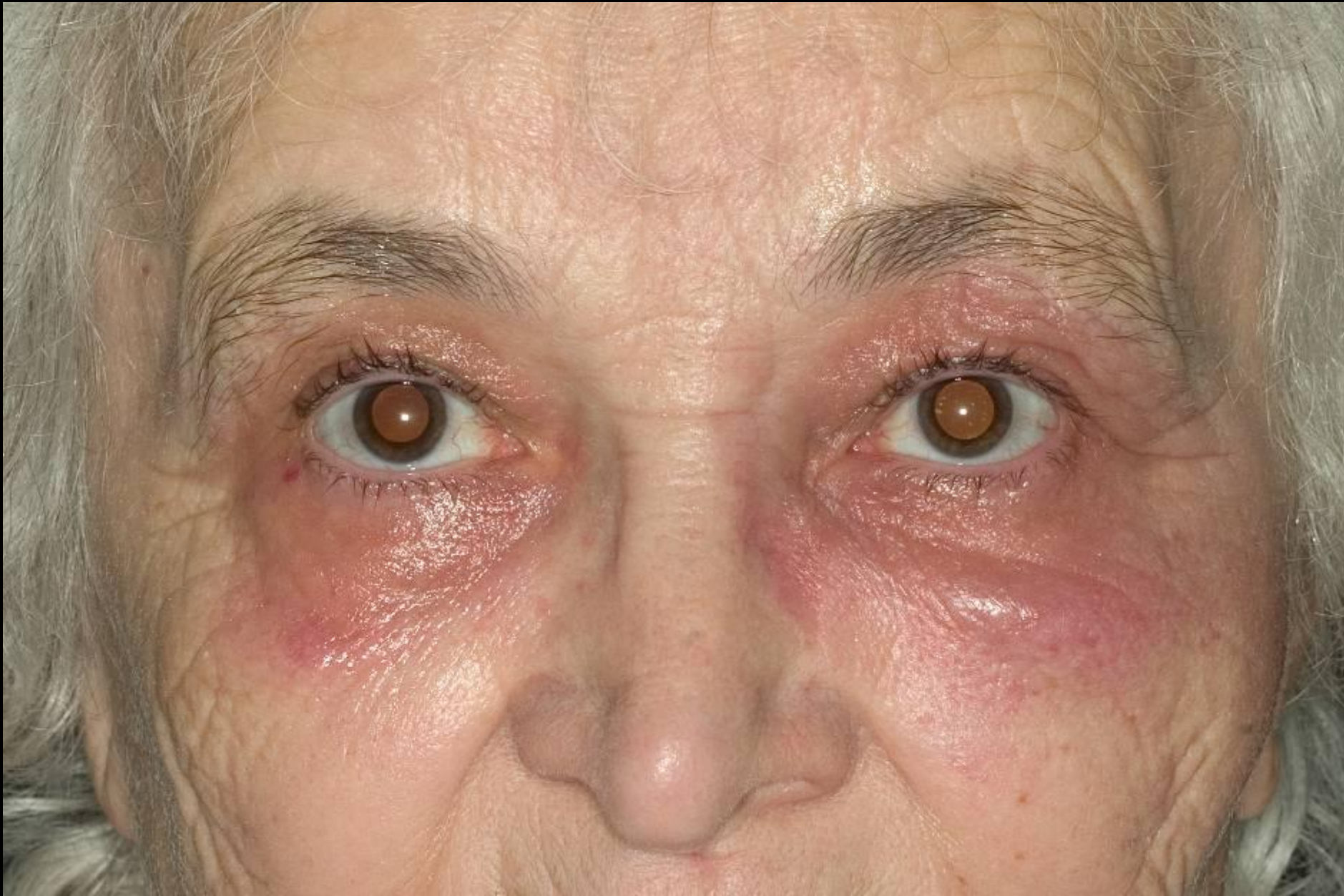cysta conjunctivae



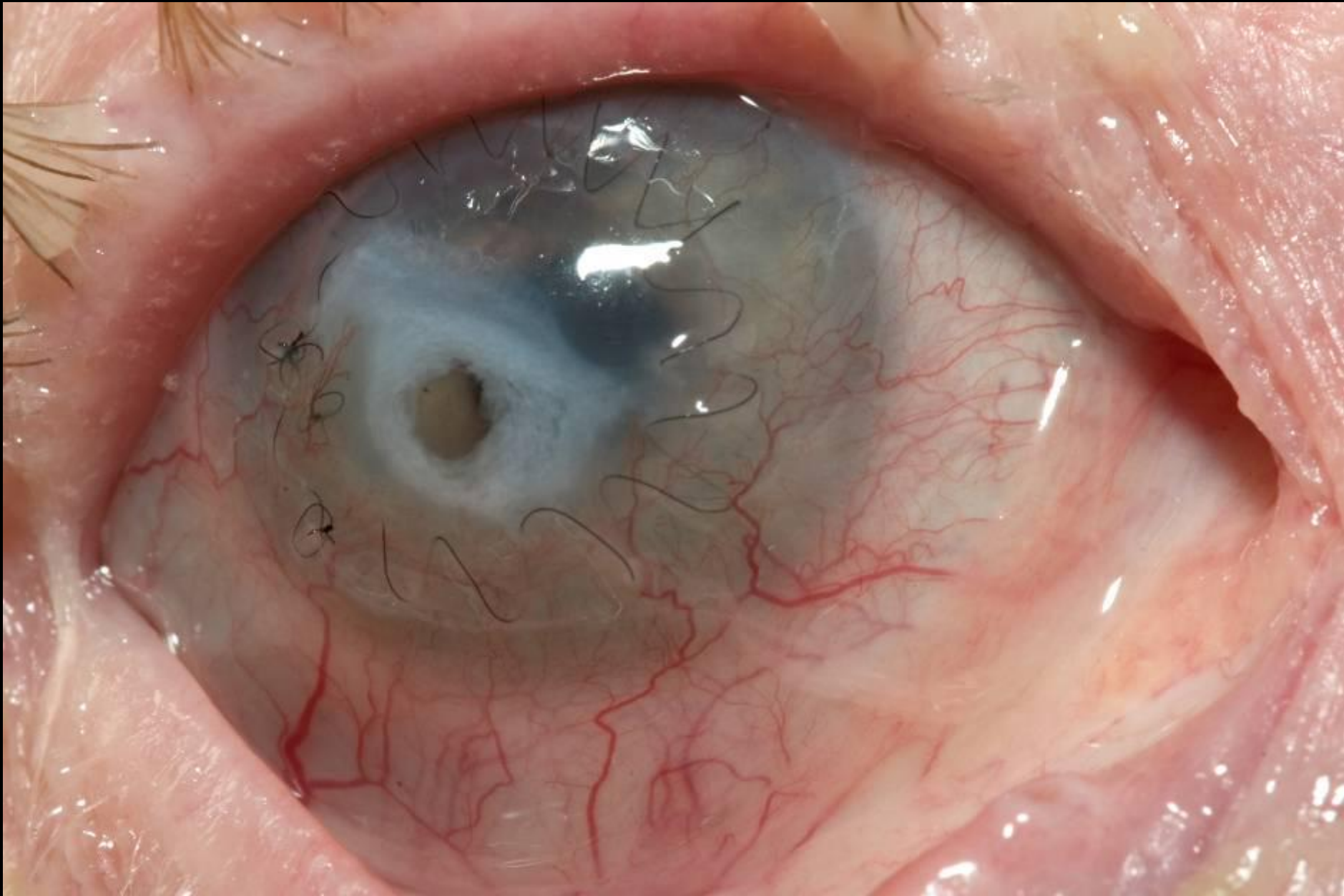
tumor iridis



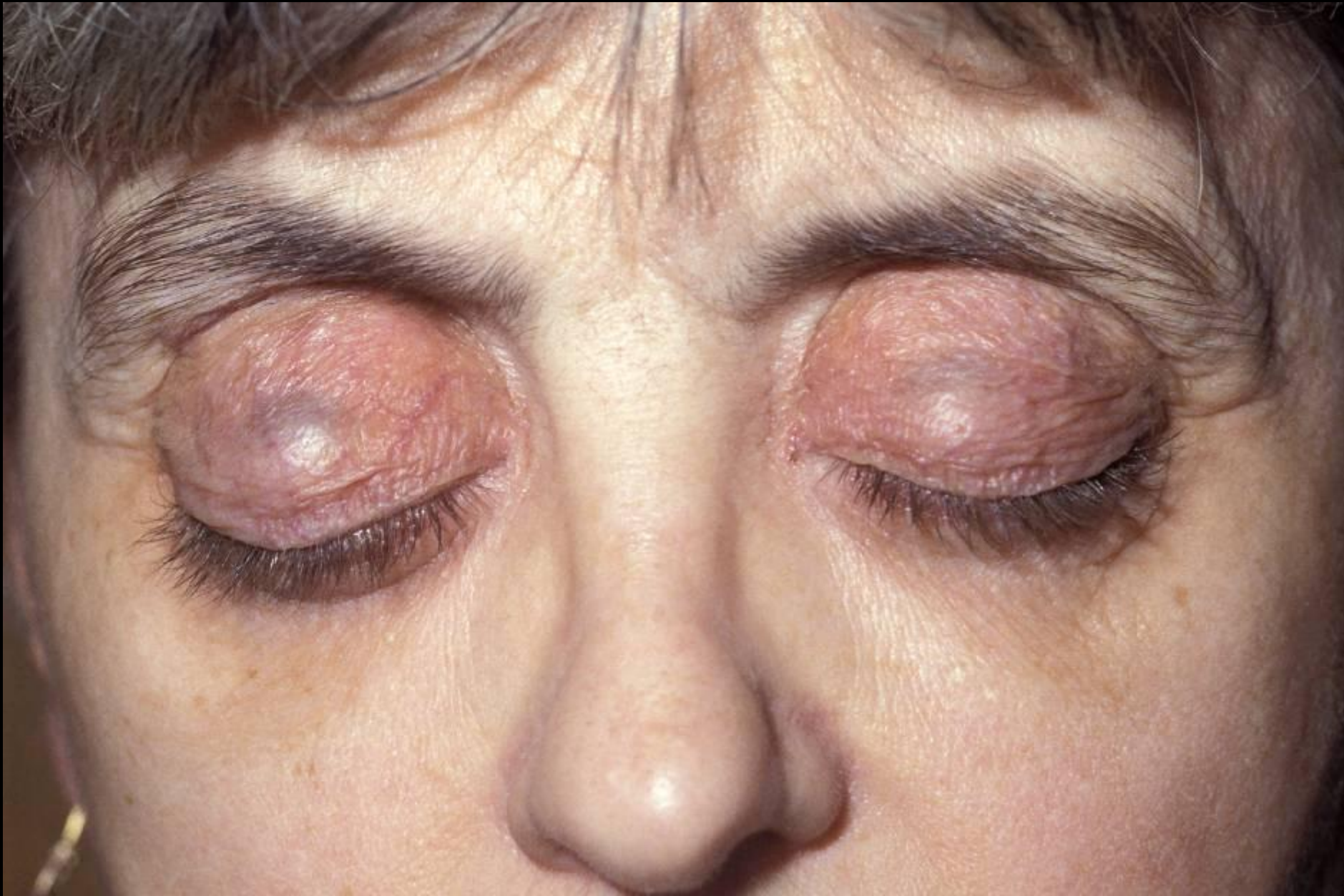dacryocystitis acuta



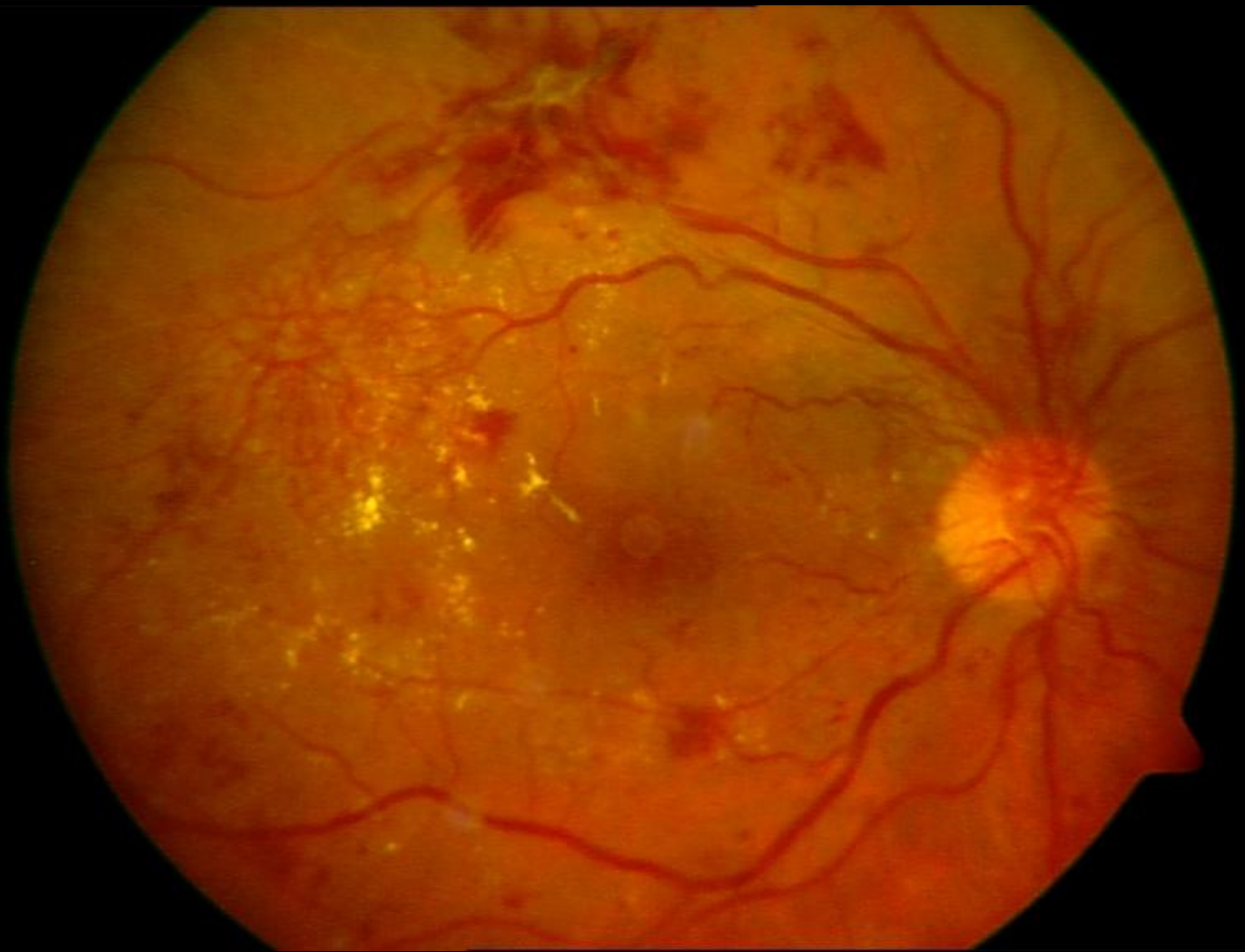dermatitis palpebrae superiores et inferiores allergica



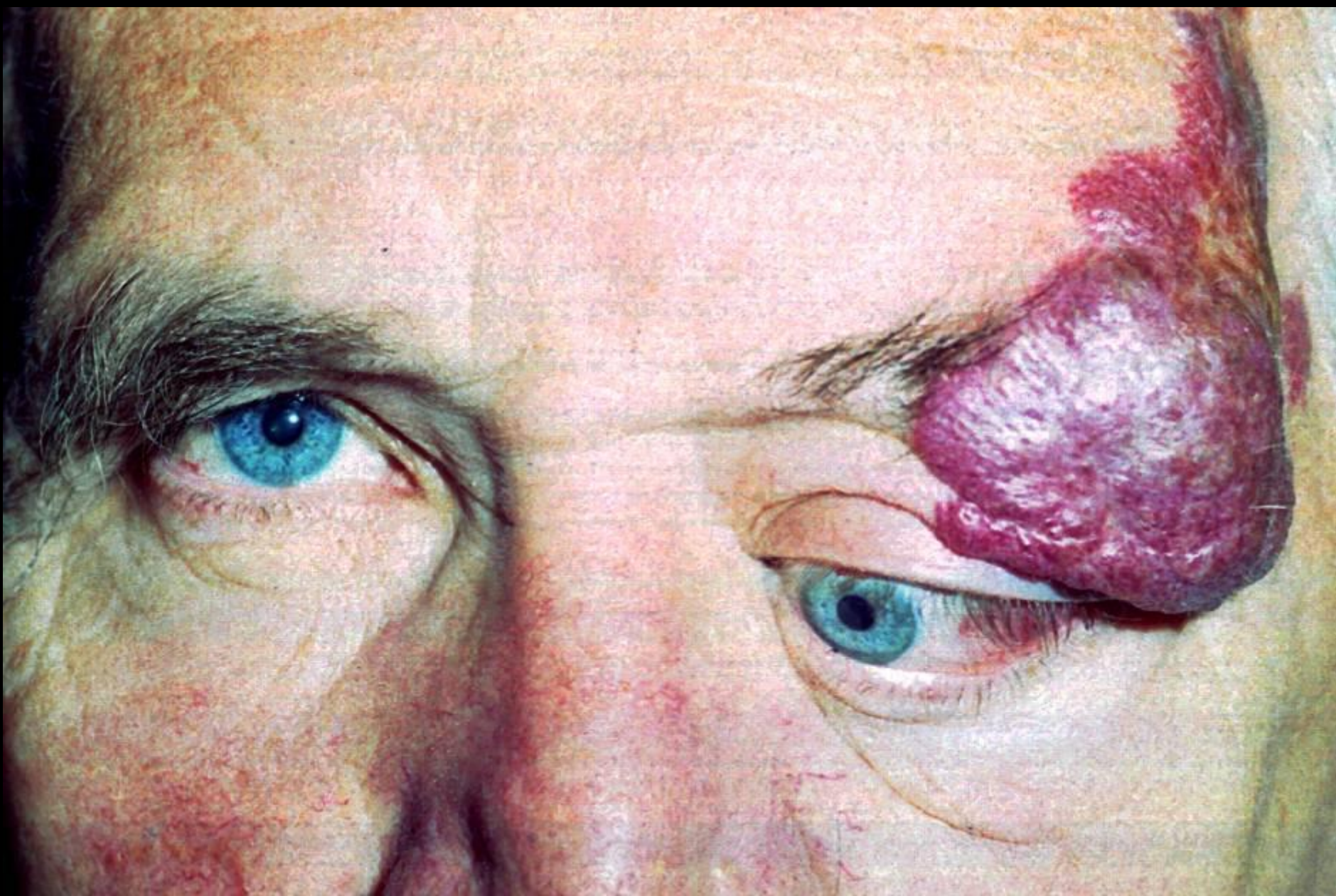descemetocele



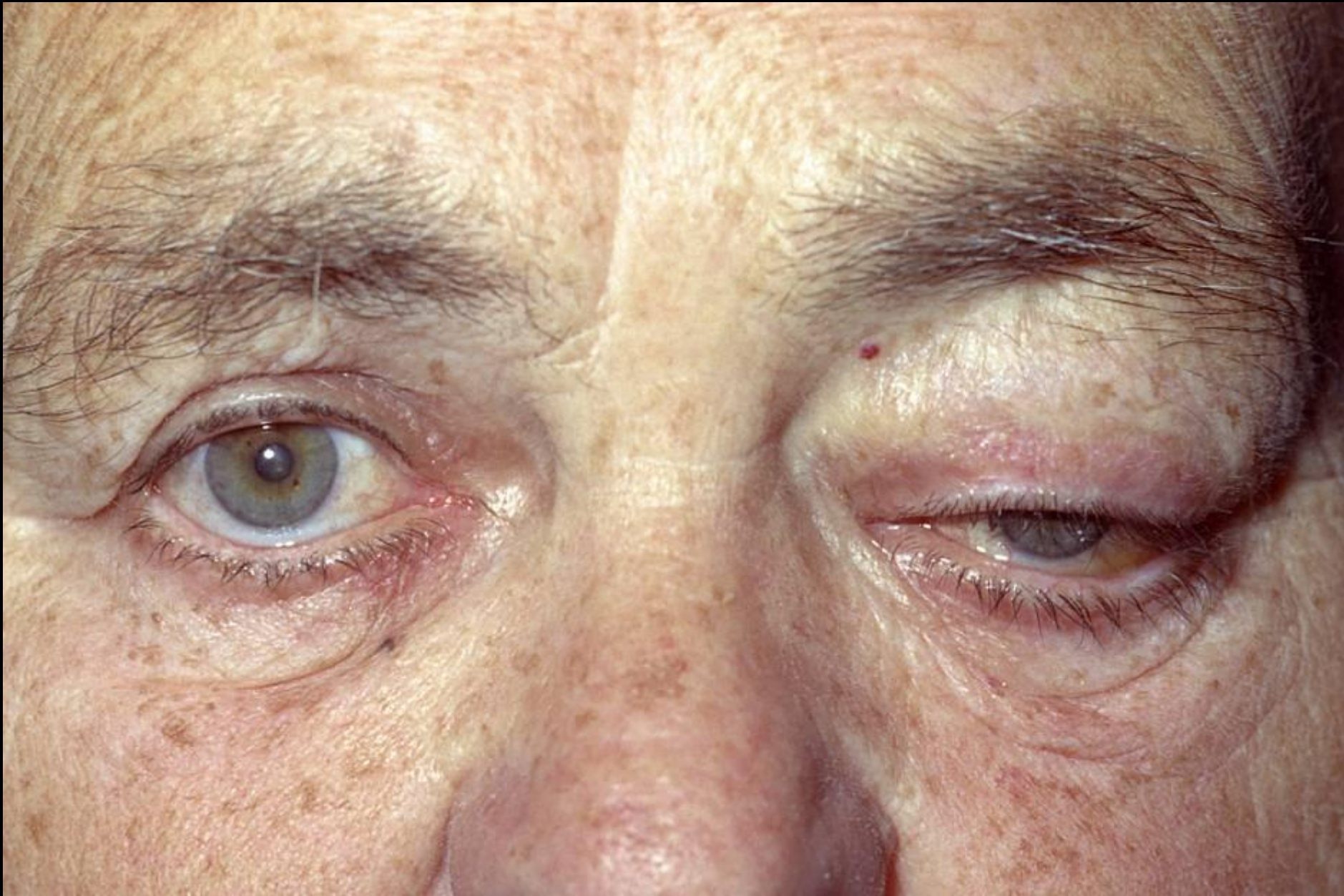
**desinsertio aponeurosim musculi levatores superiores
palpebrae superiores**



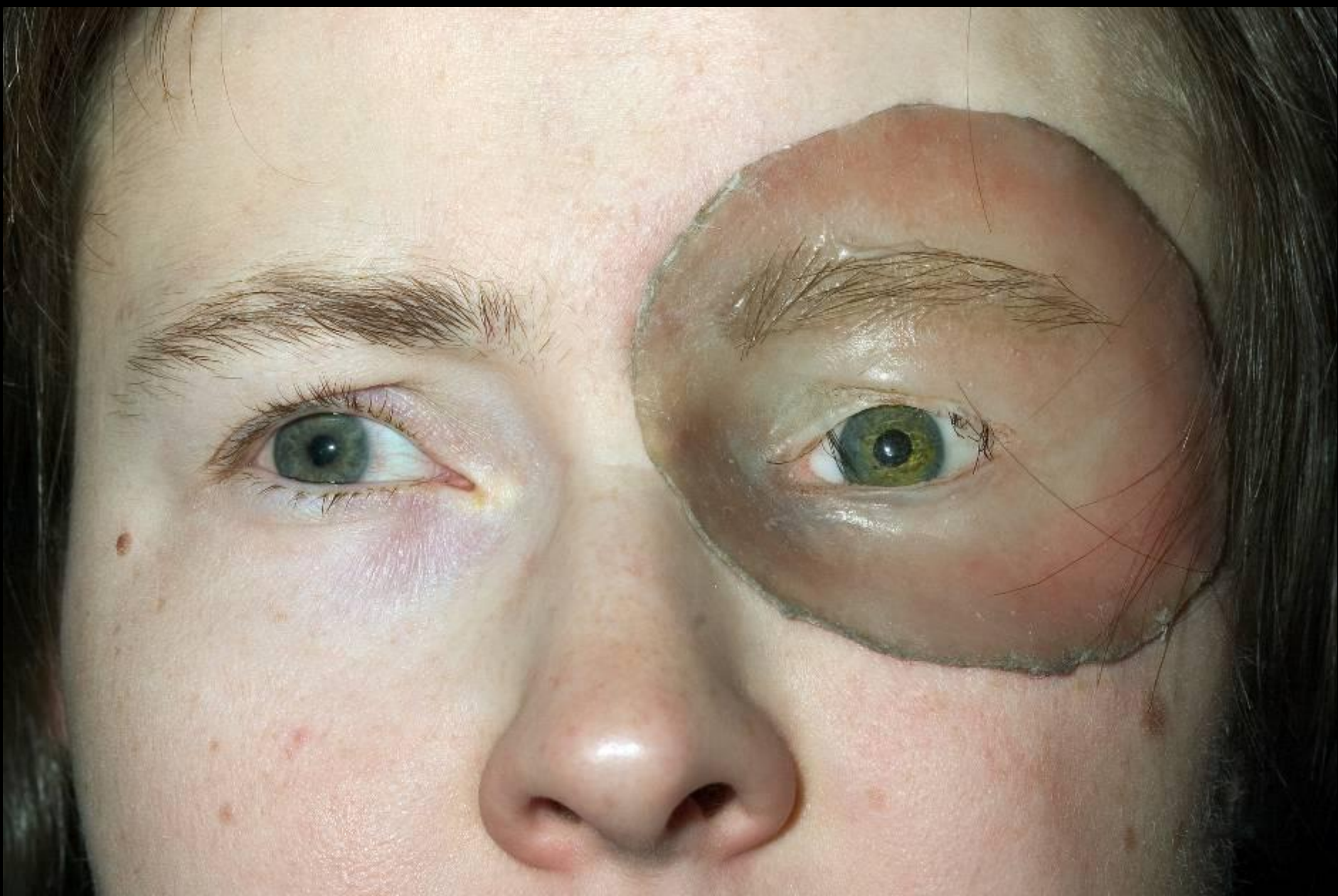retinopathia diabetica



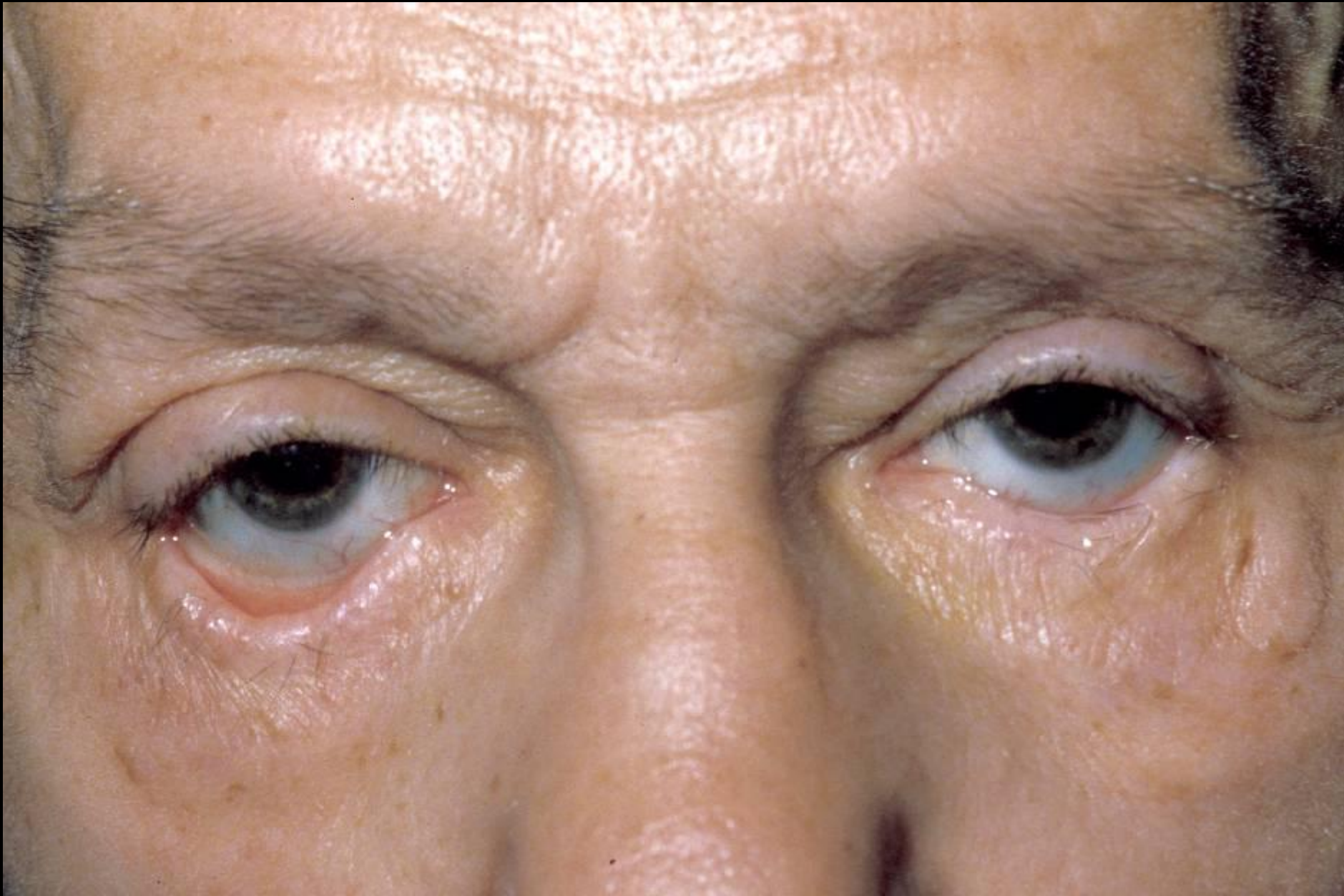
dislocatio bulbi et haemangioma cavernosum palpebrae superioris 30.



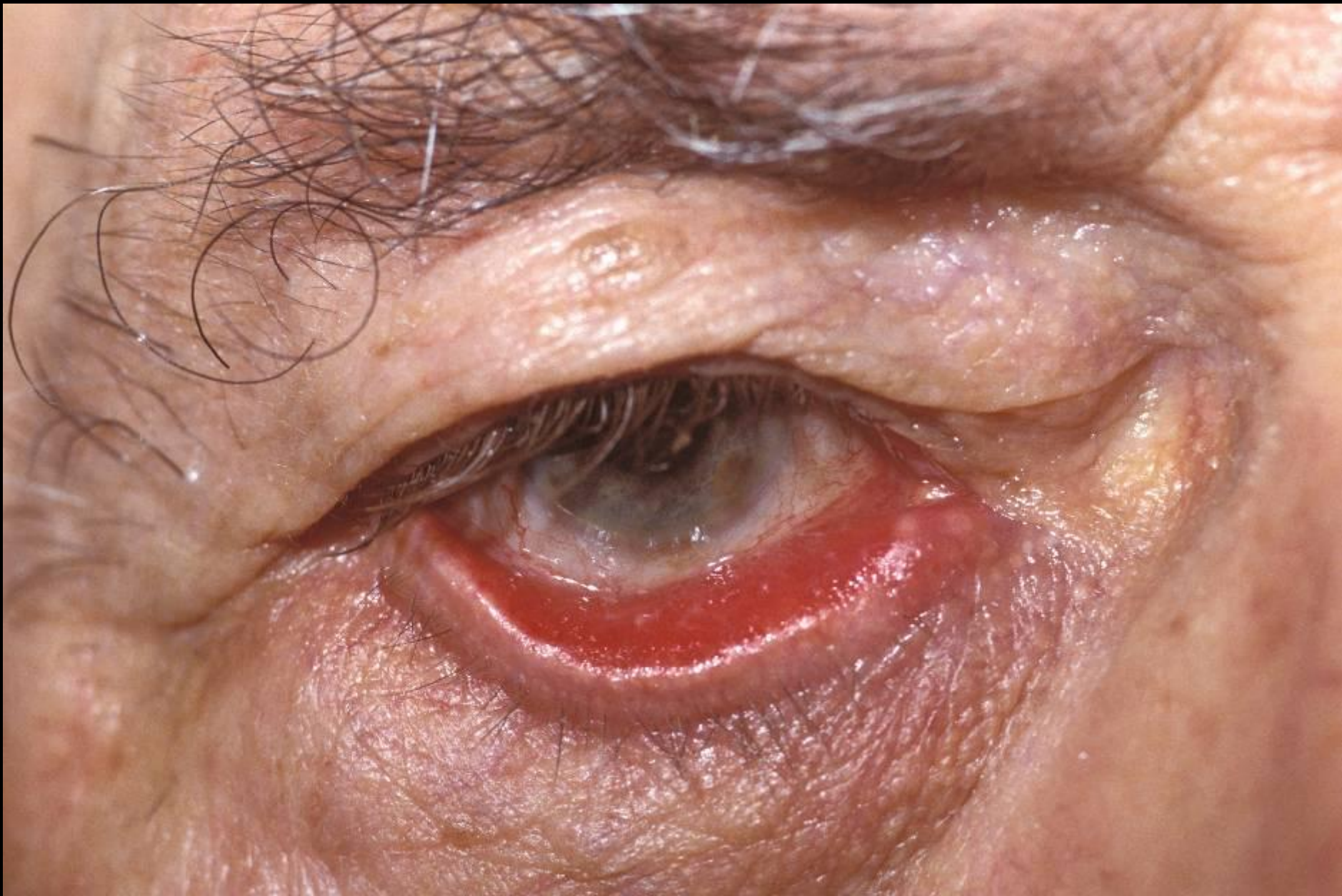dislocatio bulbi et ptosis palpebrae superioris



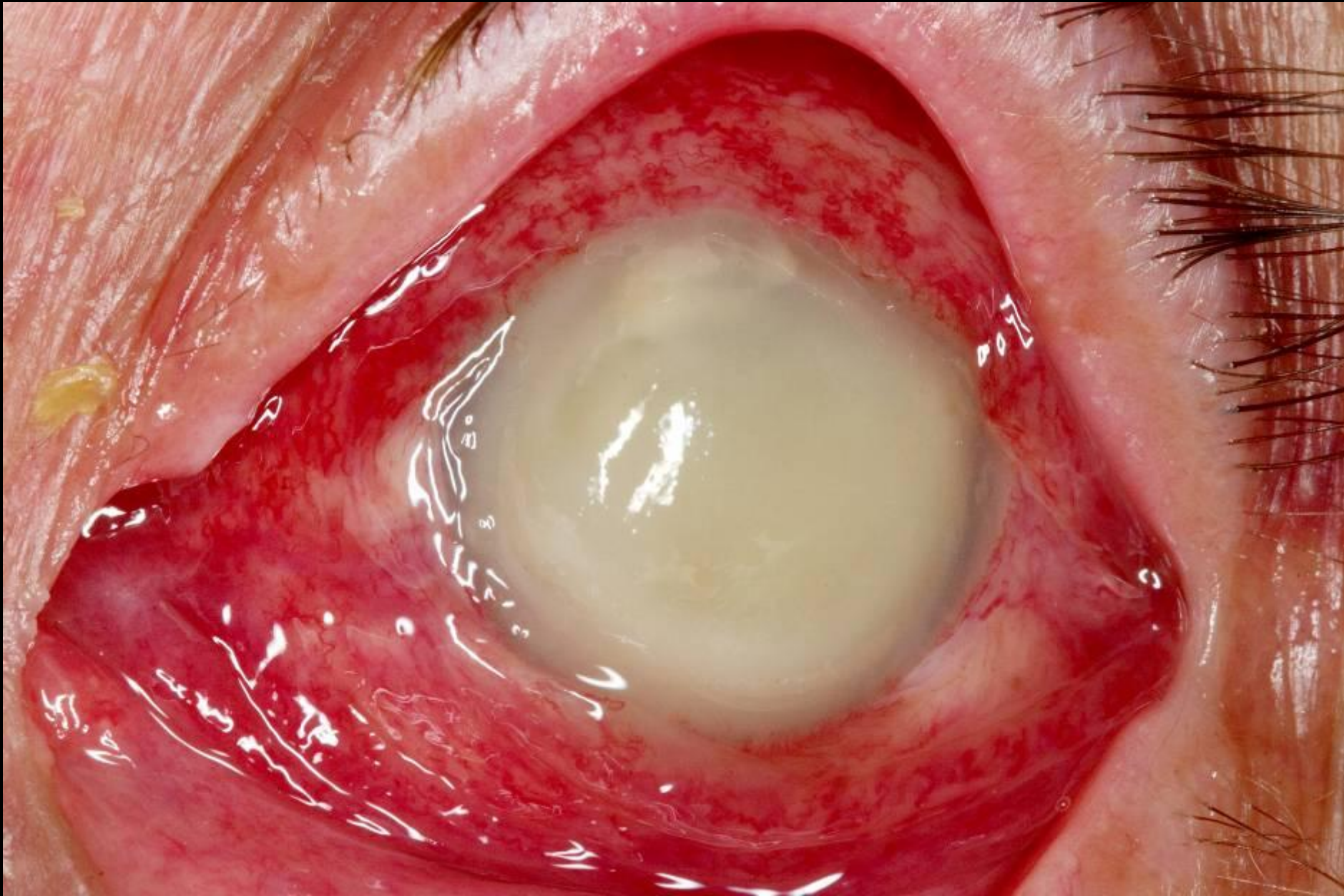ectoprosthesis



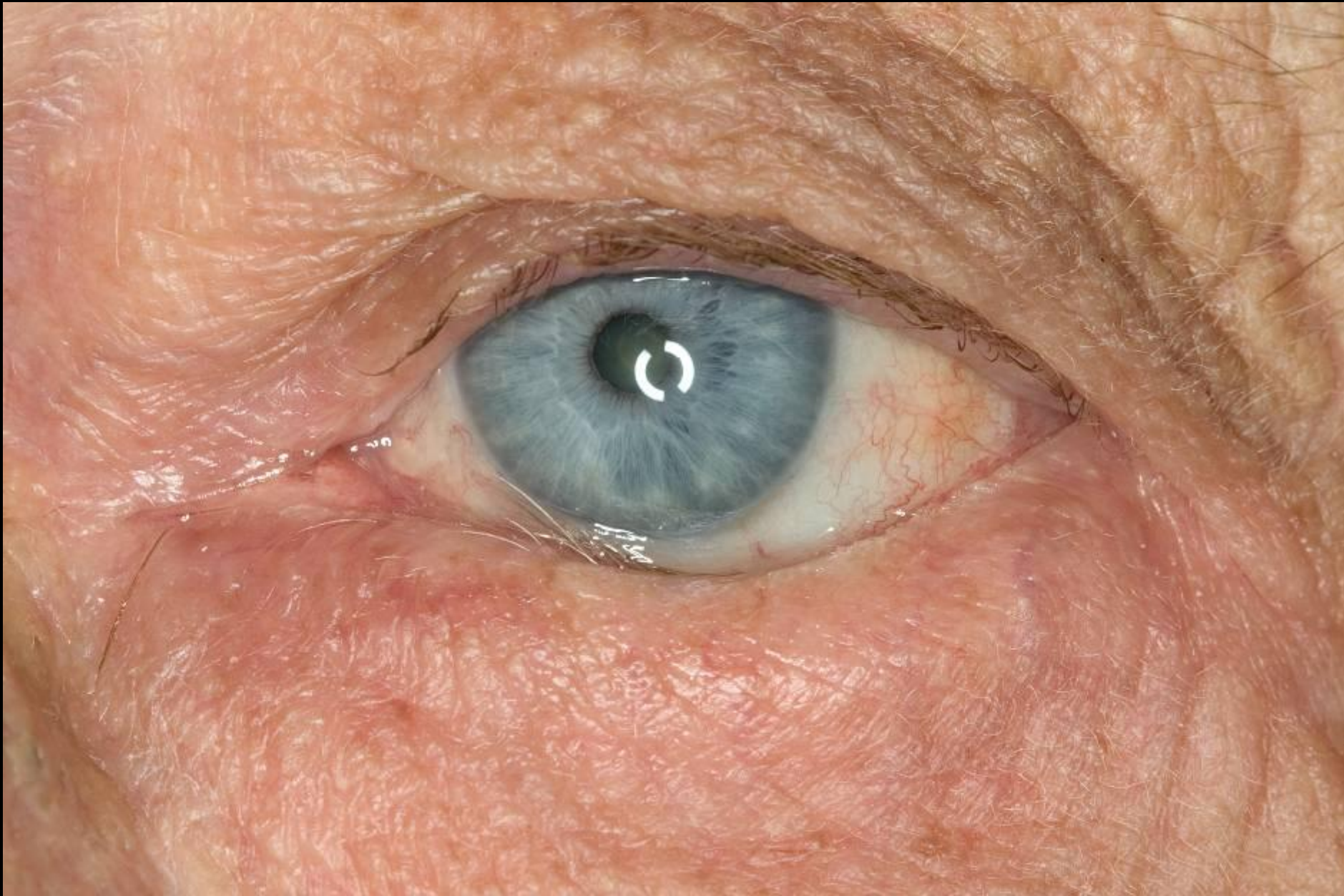ectropium cicatriceum palpebrae inferiores (jobb oldalon)



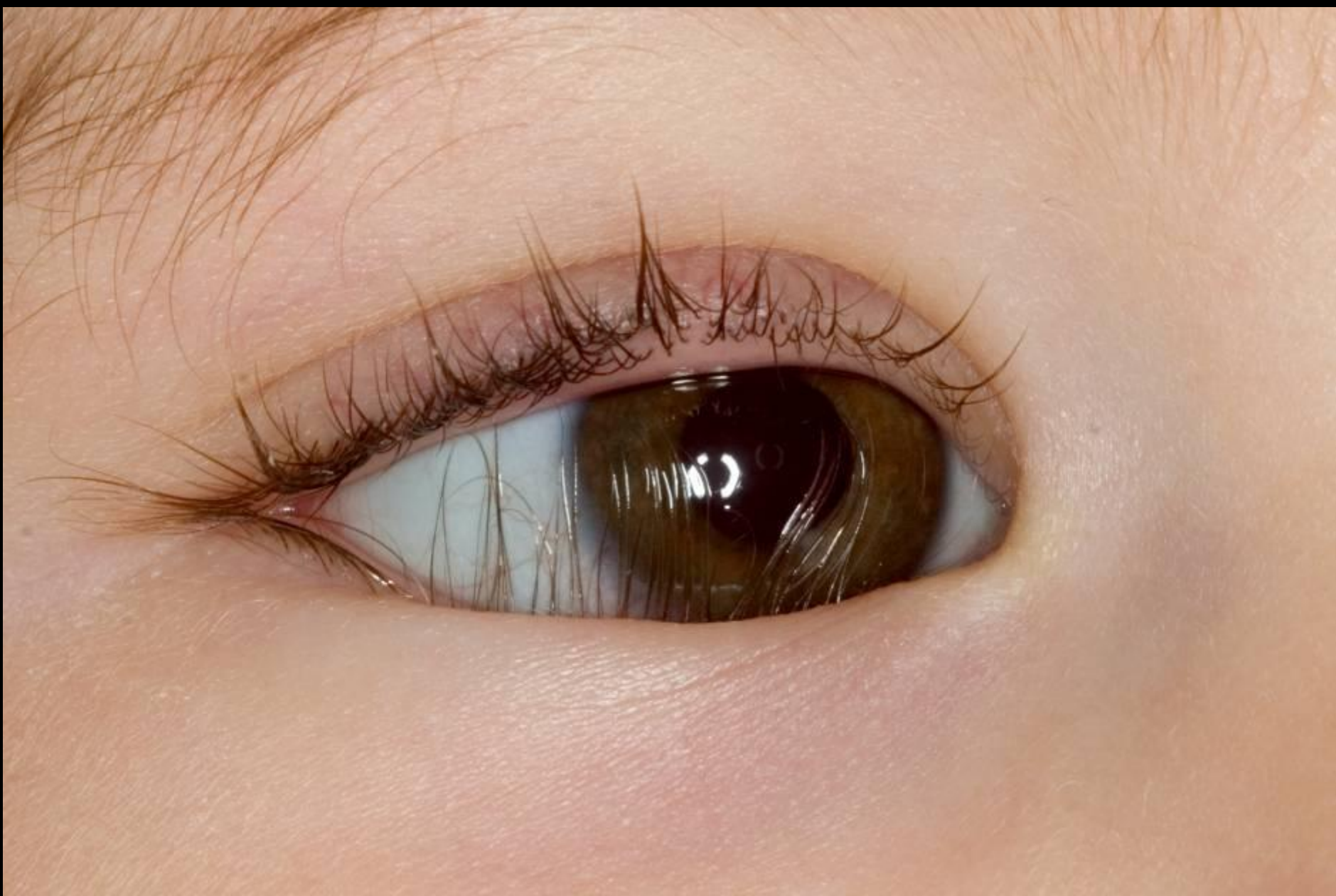ectropium senile palpebrae inferioris



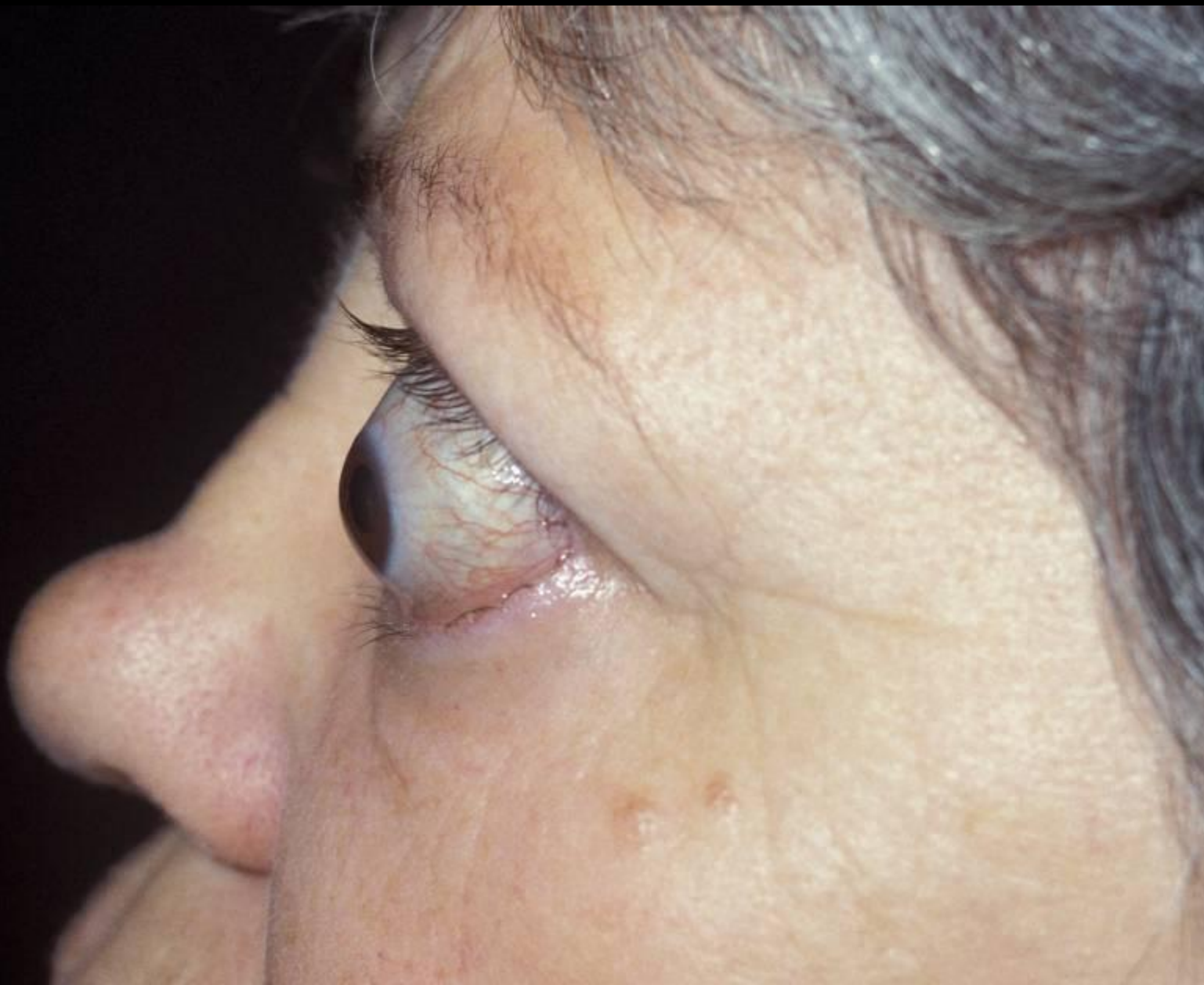
endophthalmitis



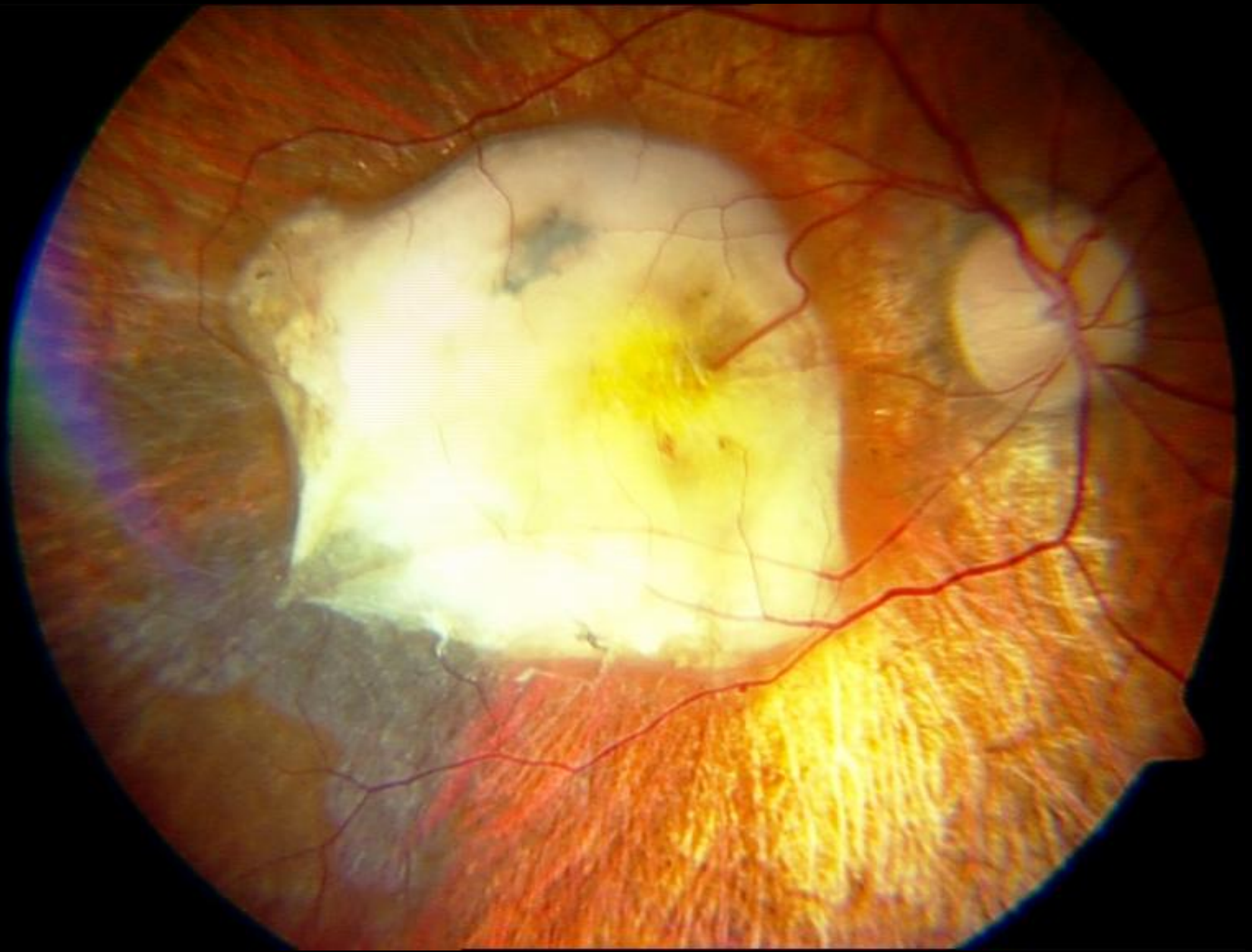
entropium palpebrae inferioris senile



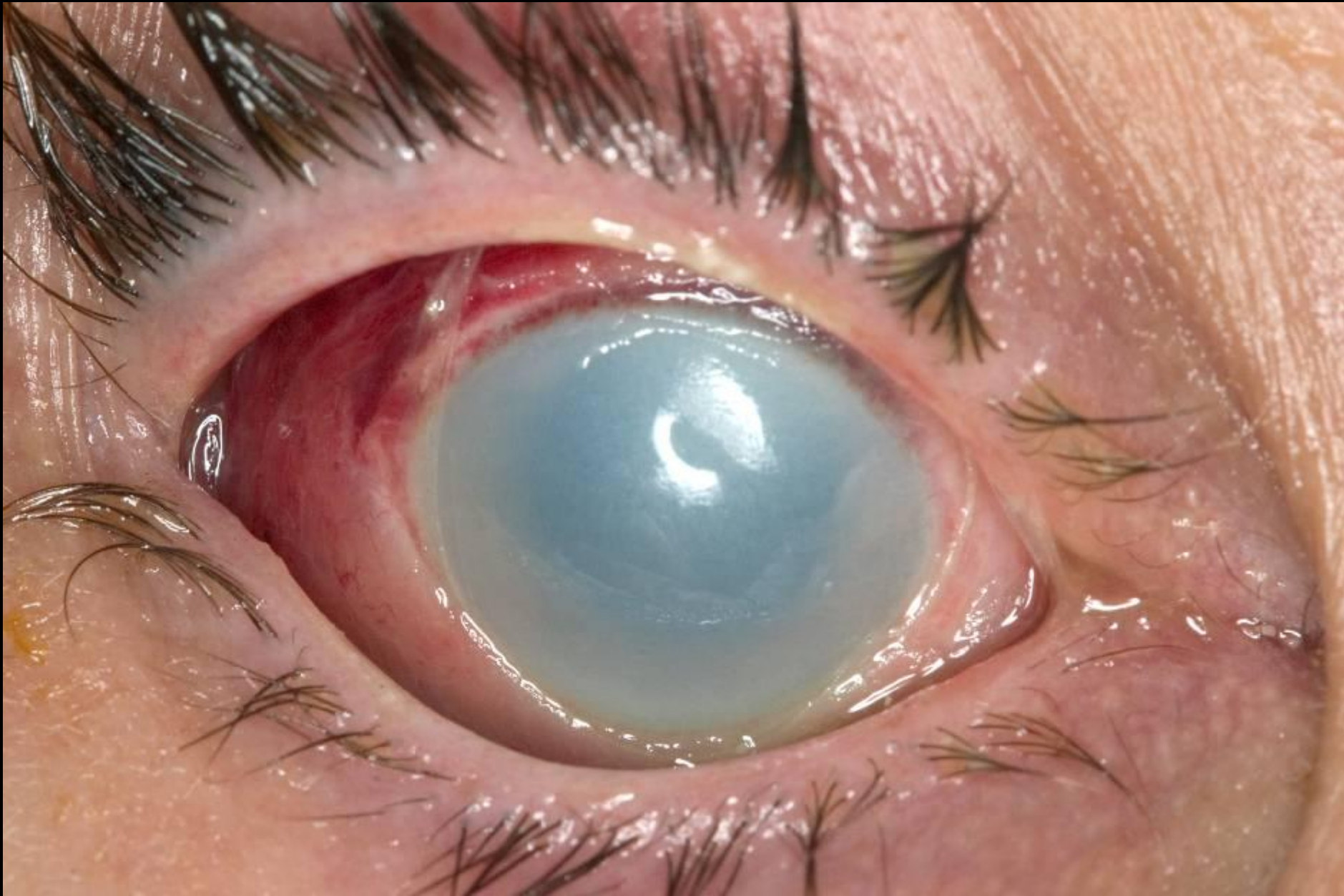entropium palpebrae inferioris congenitale



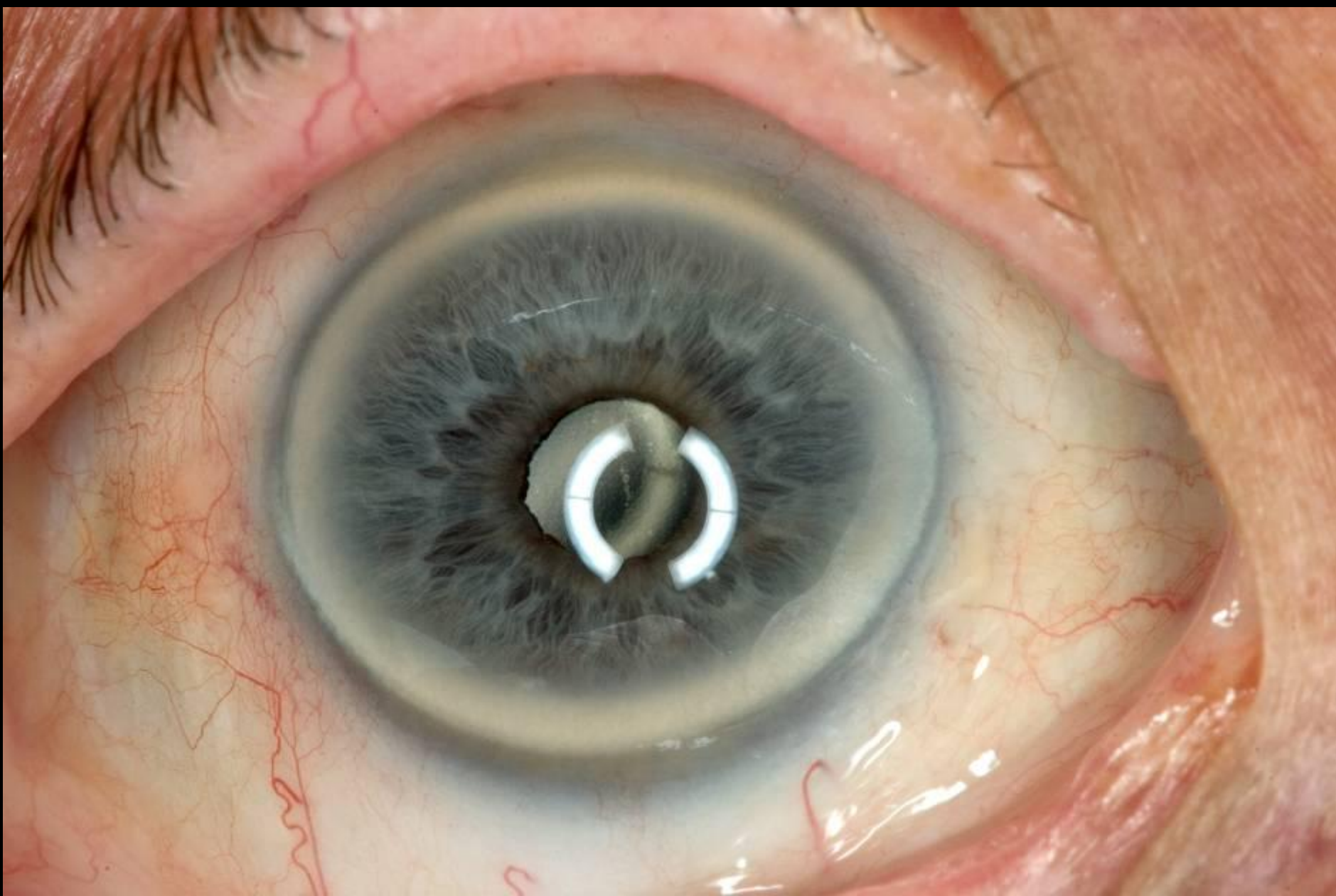
endocrin ophthalmopathy



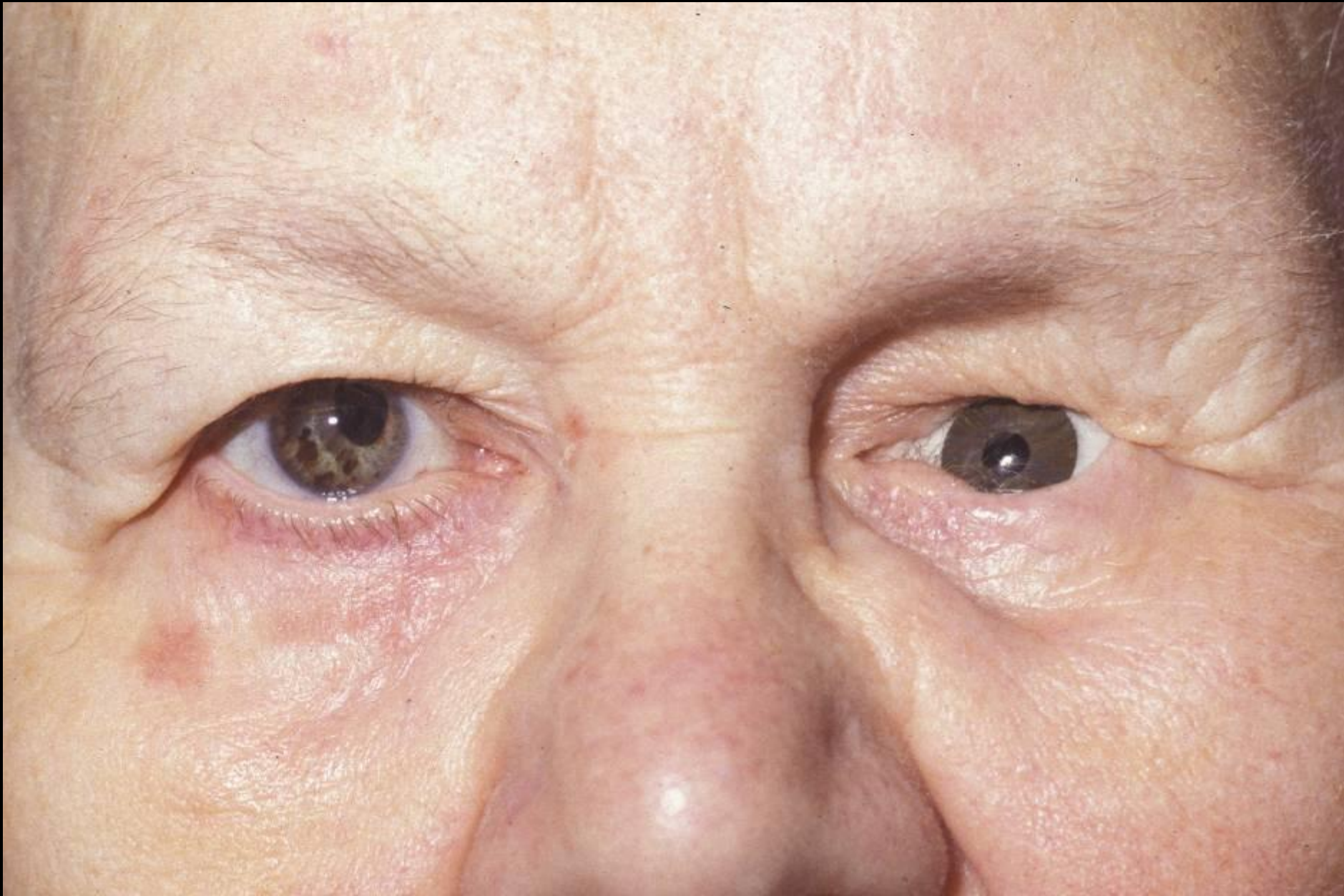
degeneratio maculae luteae exsudativa (Khunt-Junius, végstádium) 39.



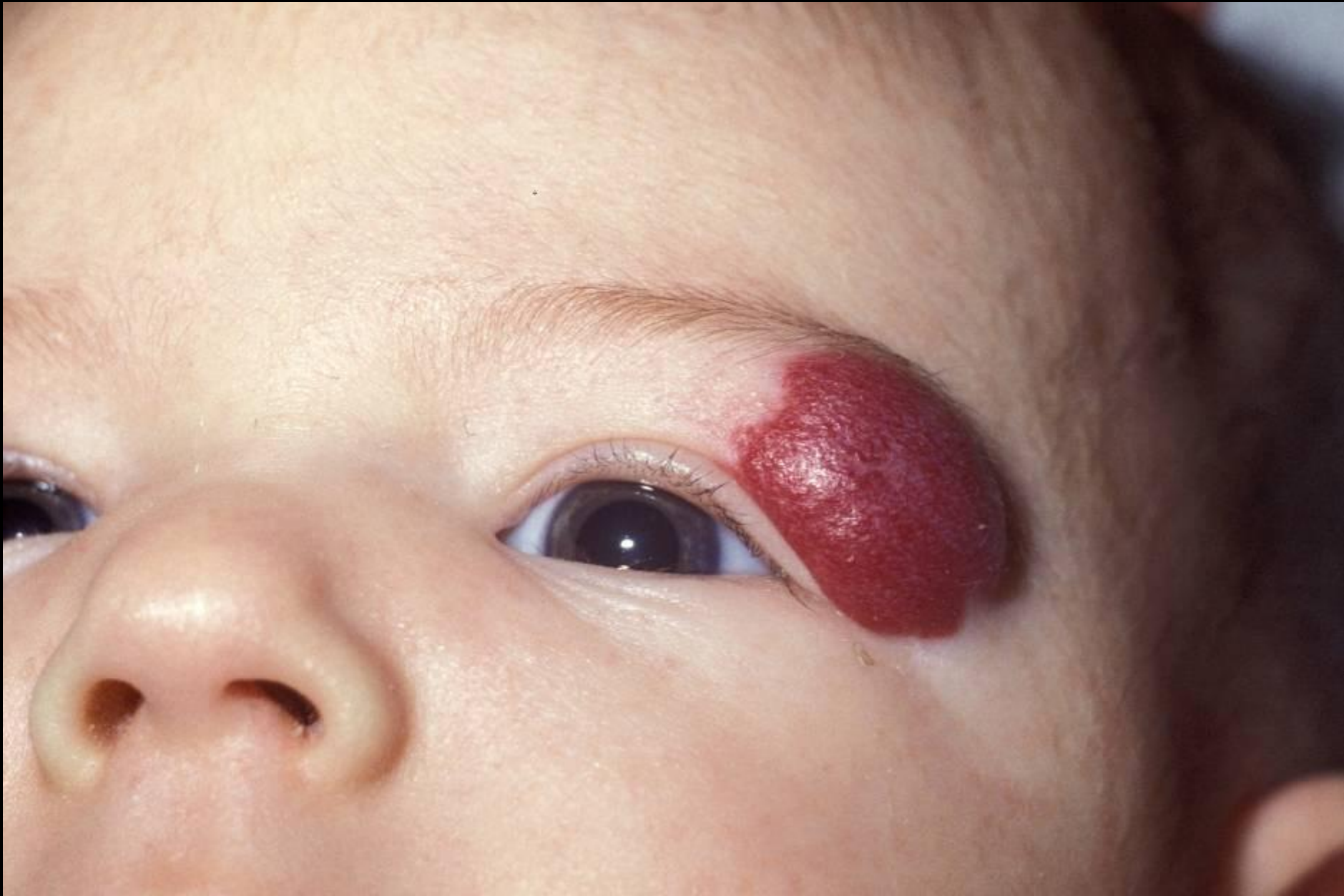**status post combustionem chimicale conjunctivae et corneae
(főttal szem)**



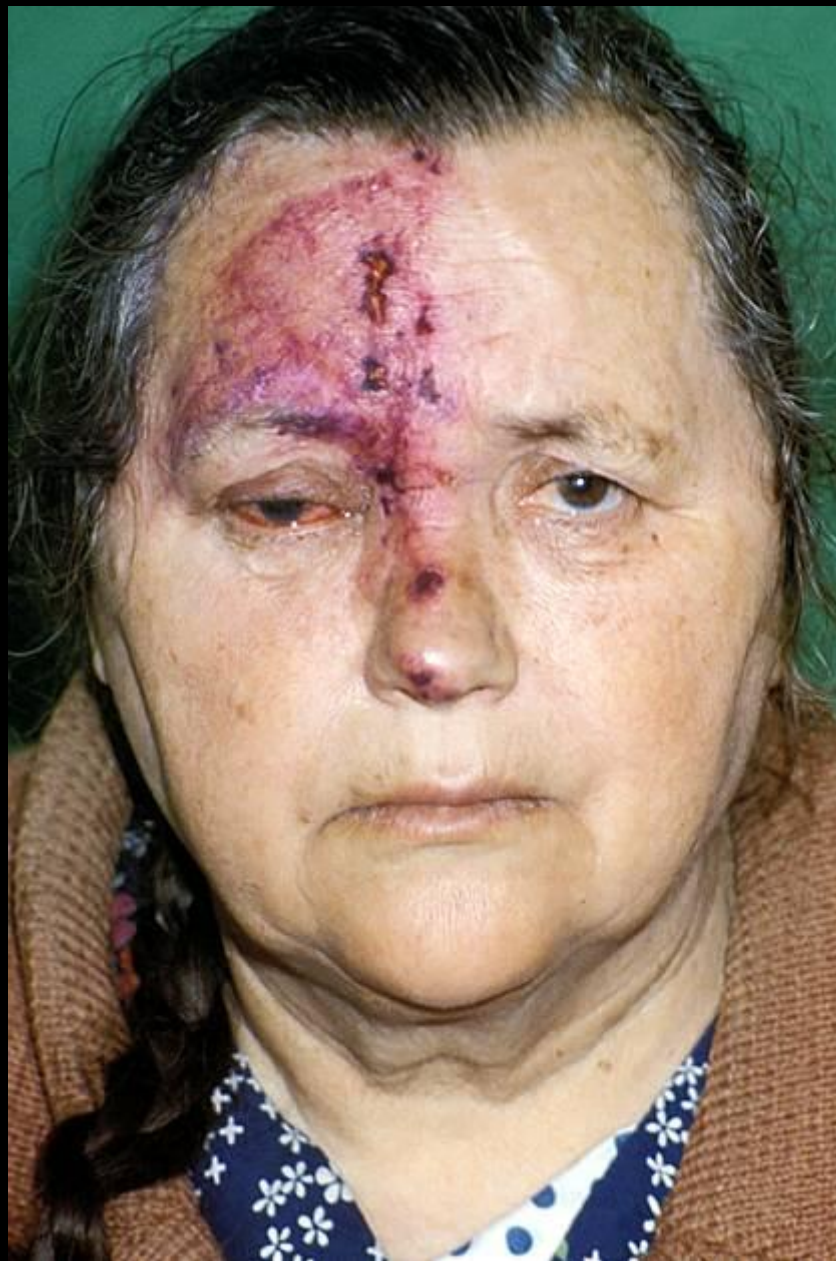arcus senile corneae (Gerontoxon)



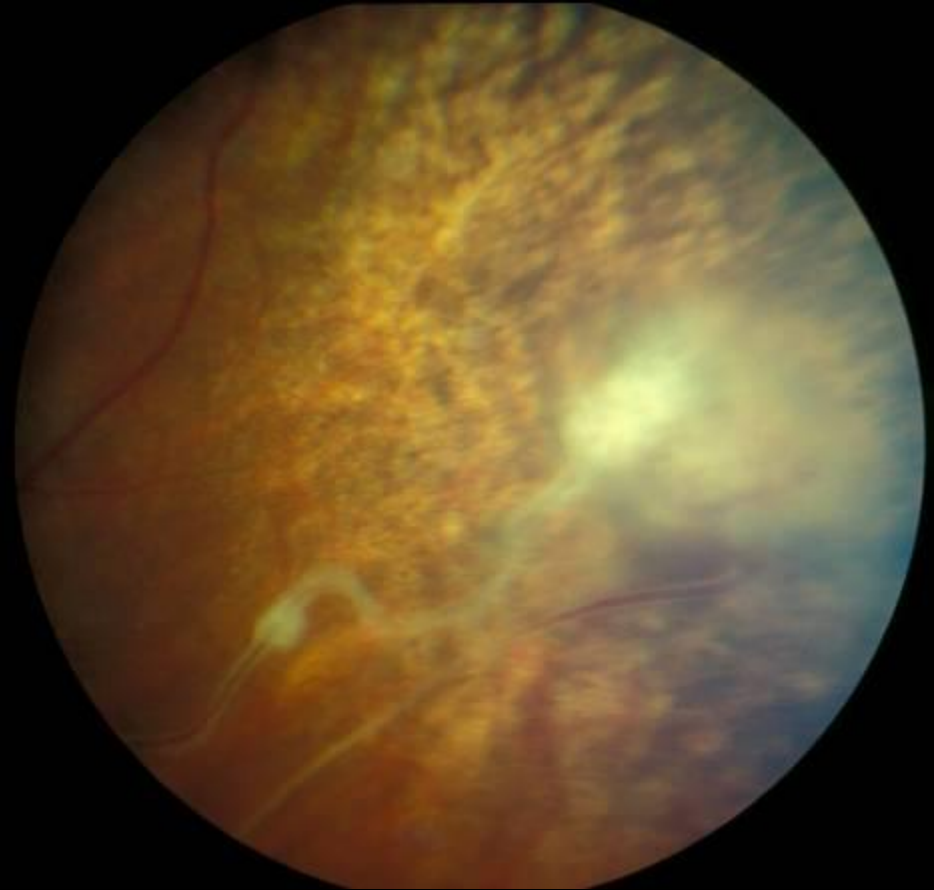
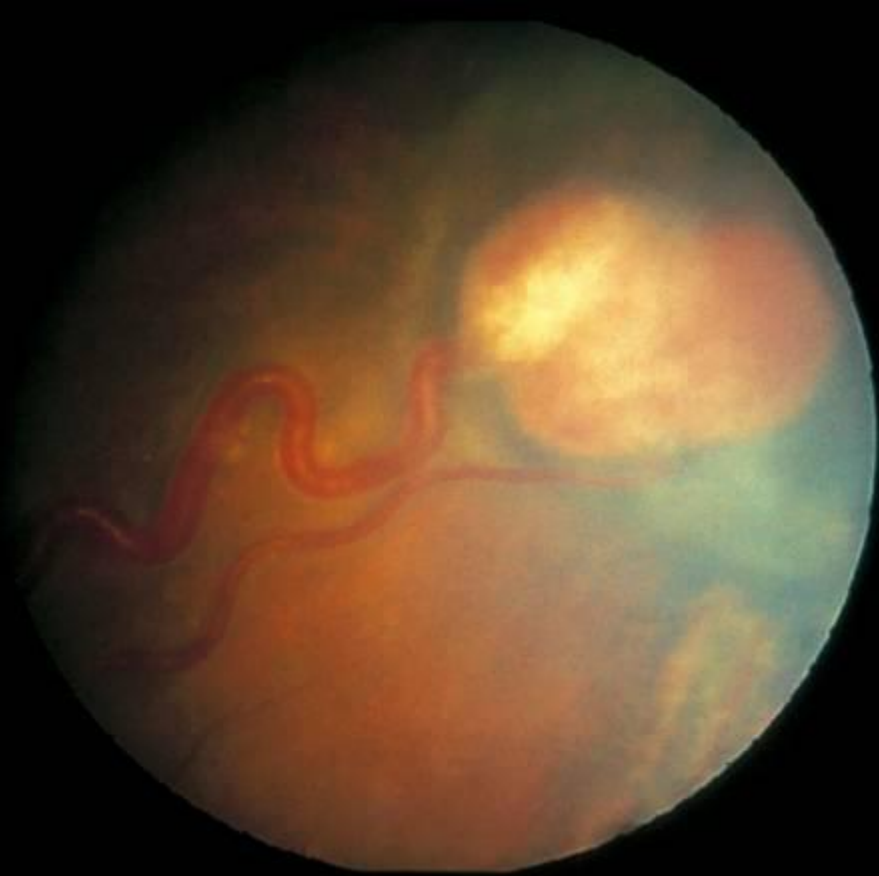
prothesis bulbi (bal oldalon)



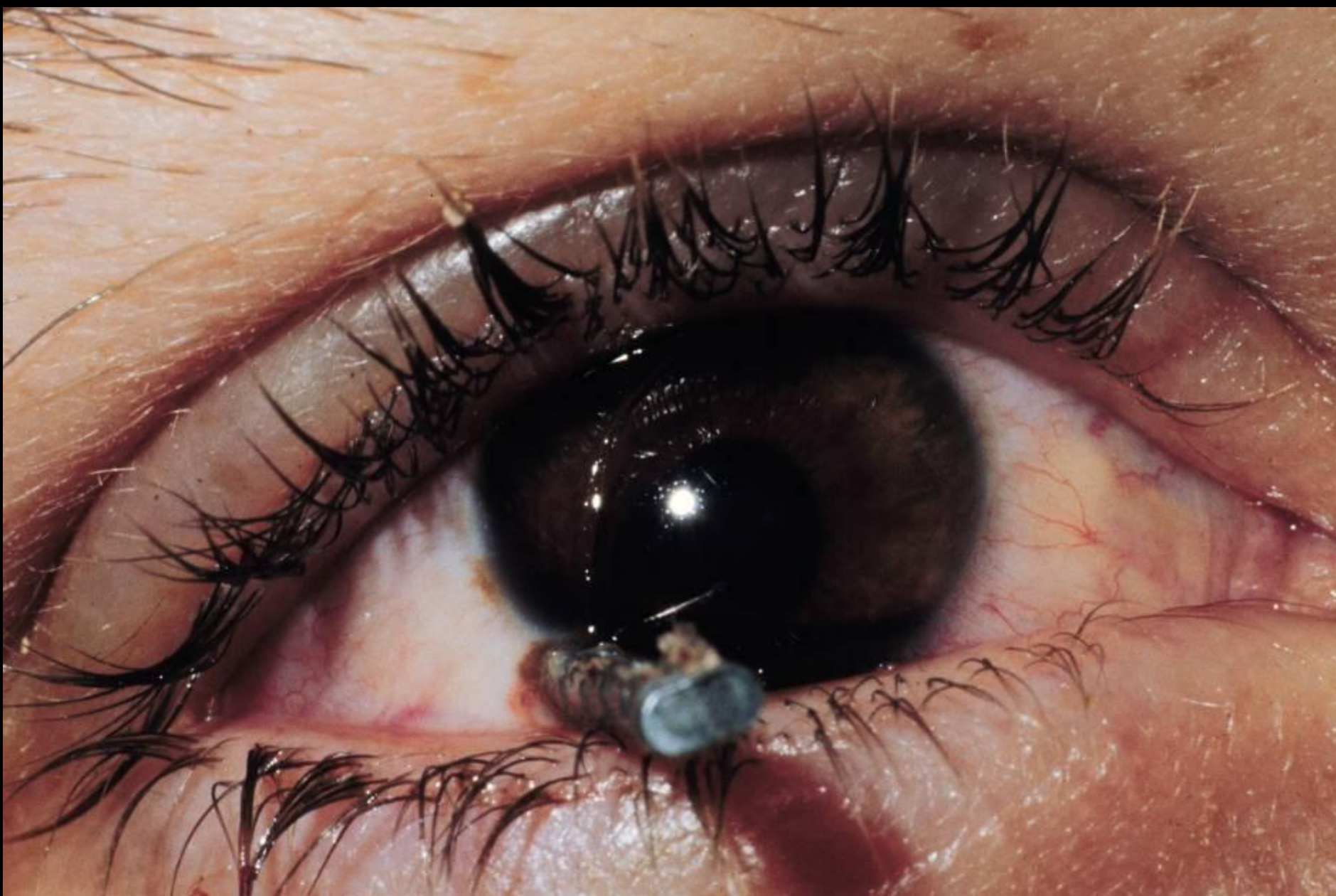haemangioma palpebrae superioris



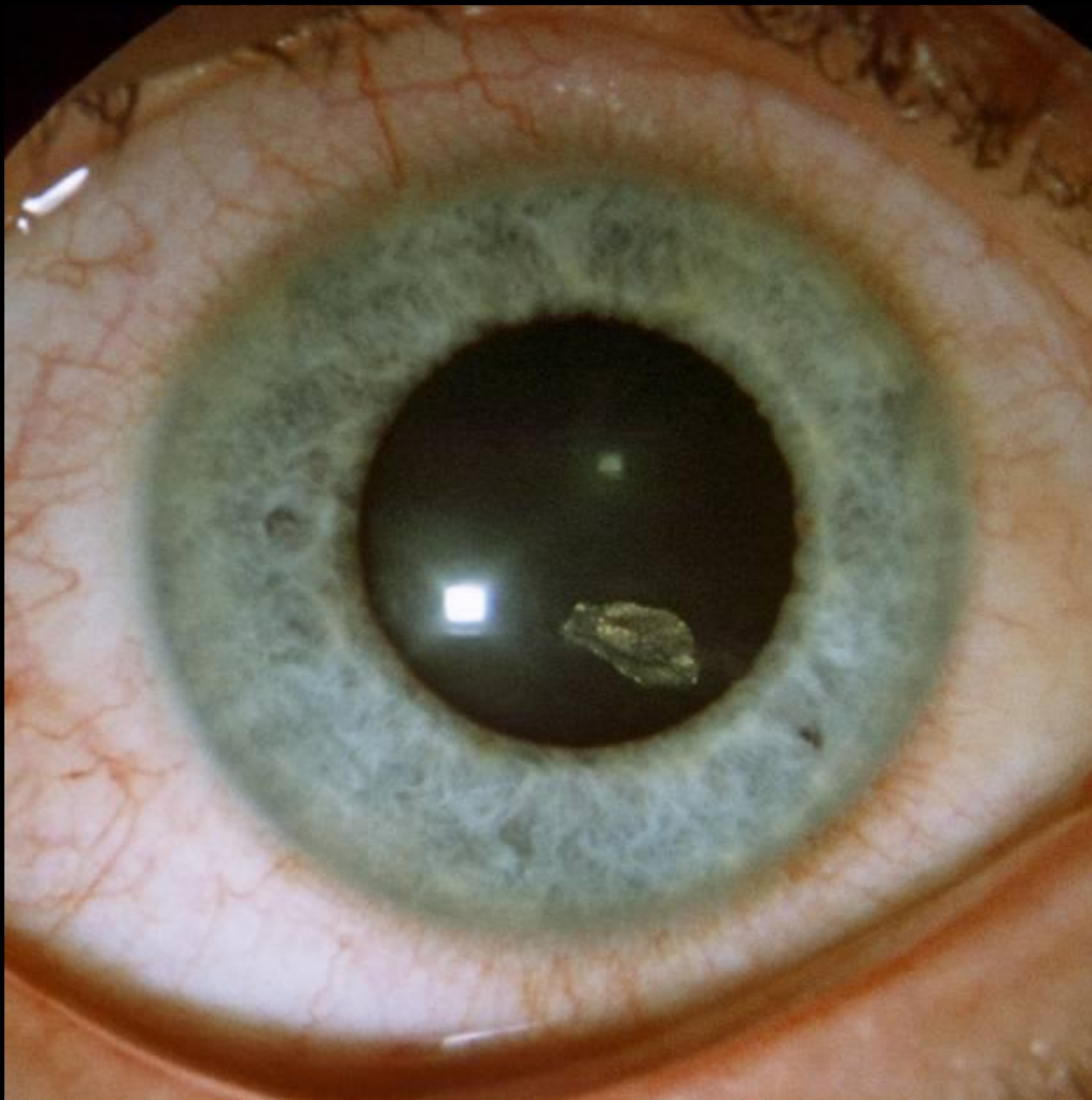
herpes zoster faciei



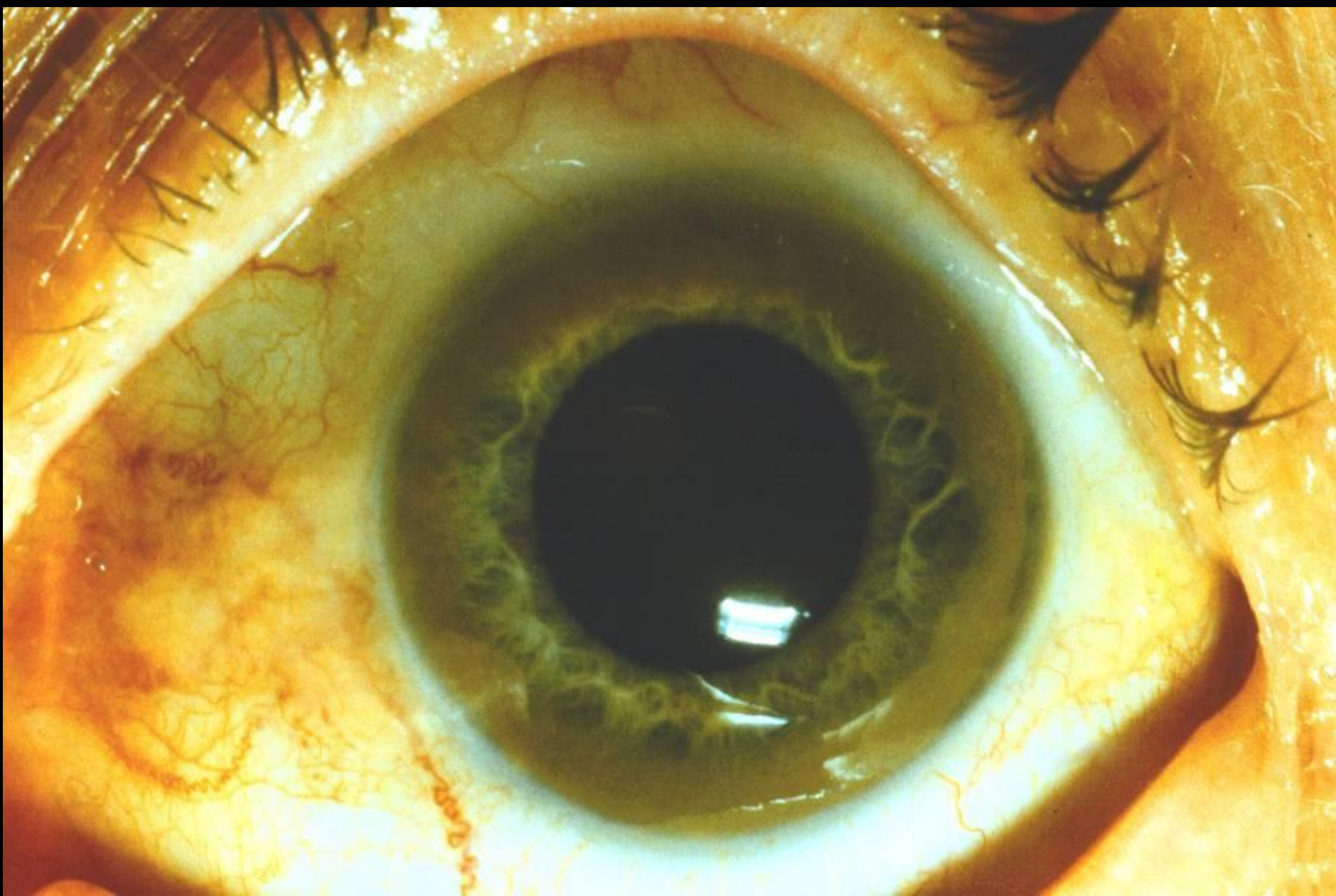
**haemangioma arteriae retinae Hippel betegségben
(irradiáció előtt és után)**



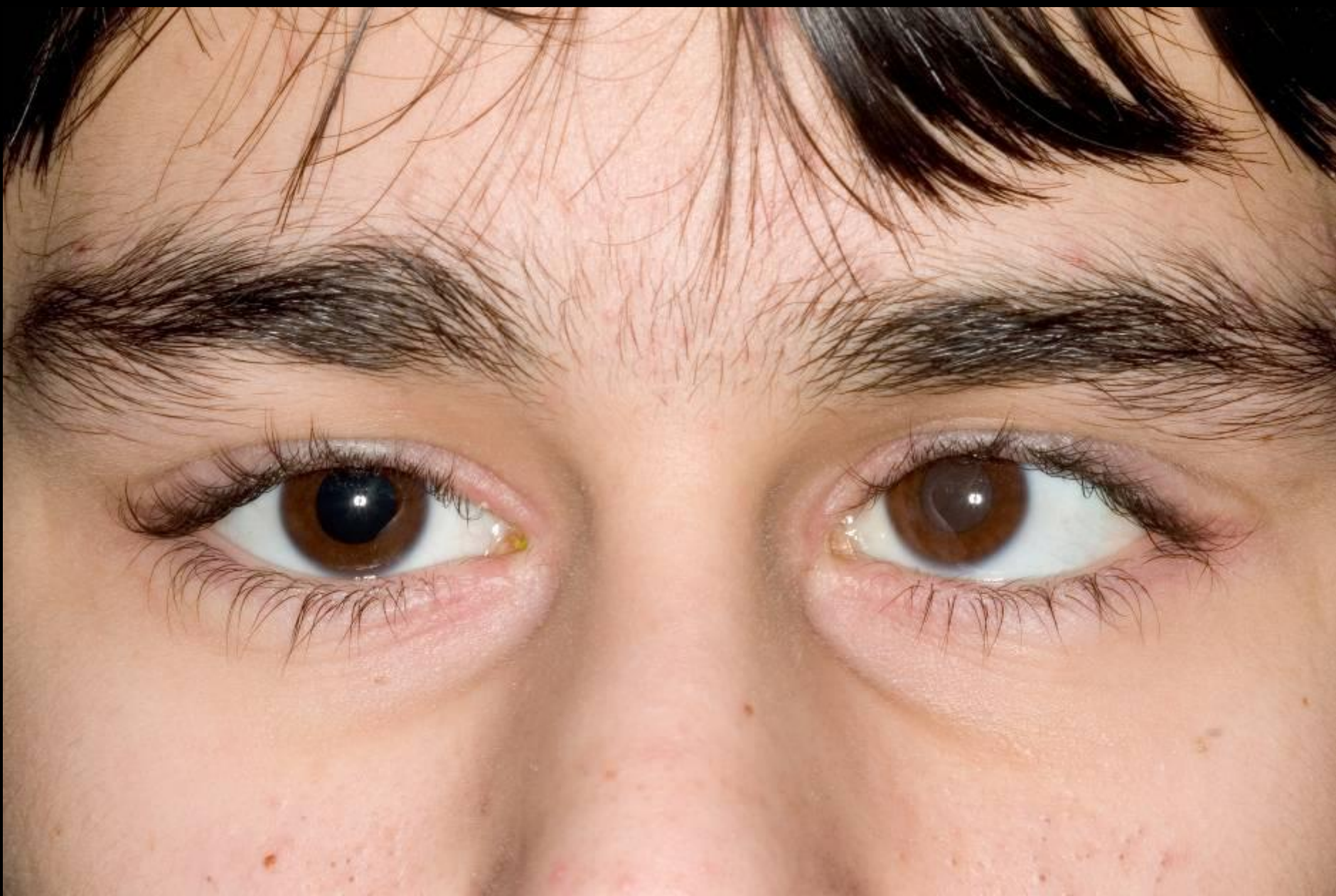corpus alneum bulbi



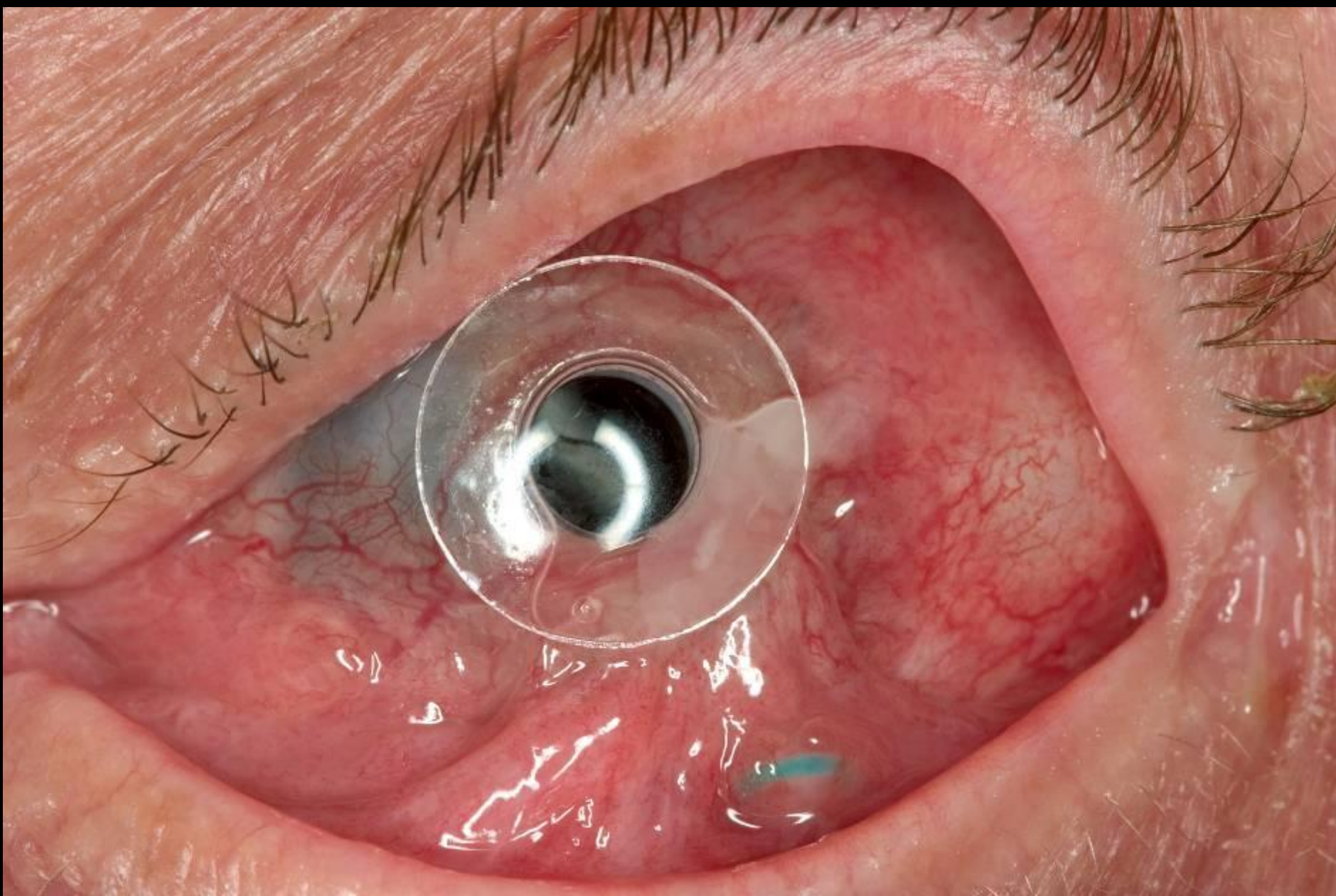
corpus alneum lentis



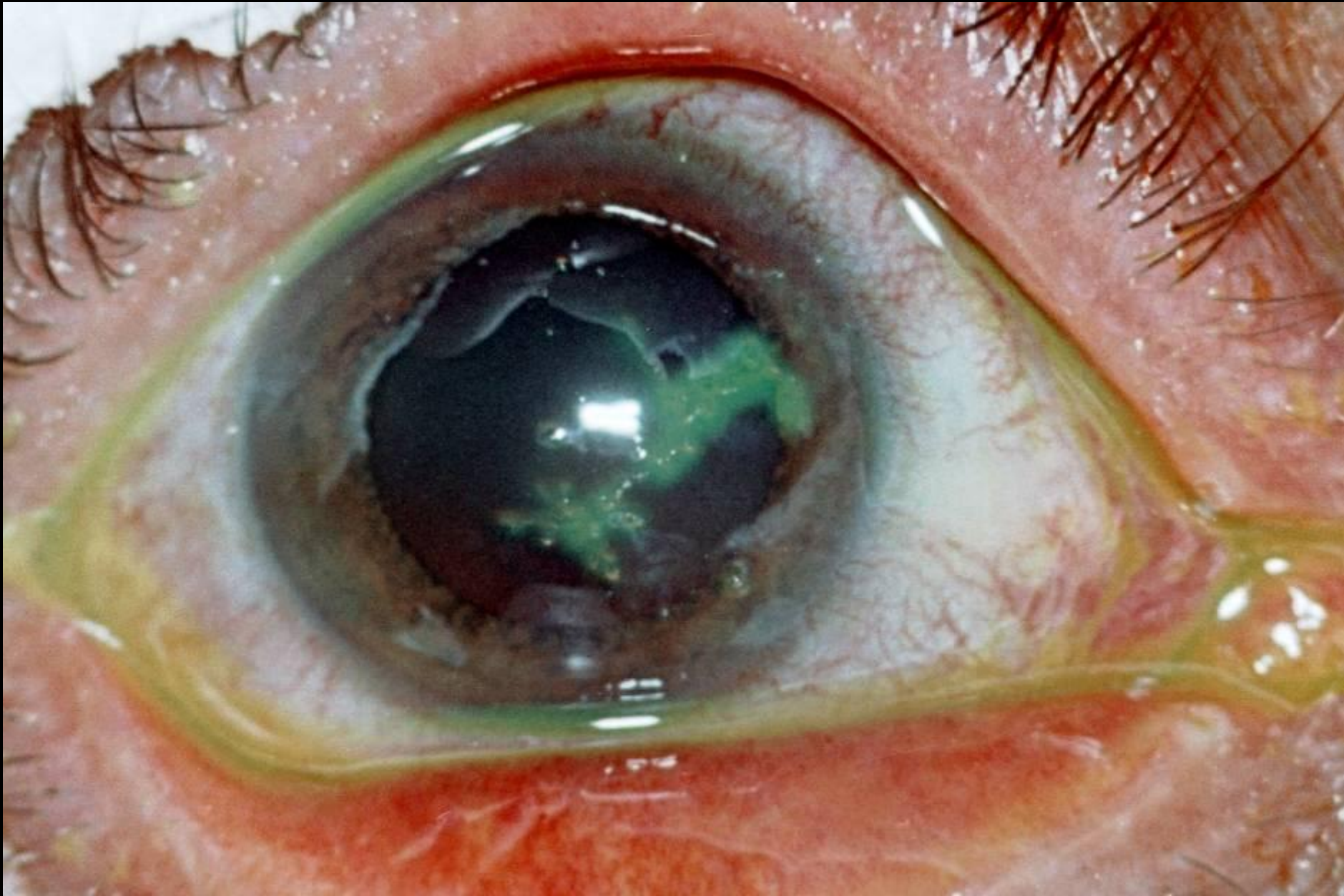
Kaiser-Fleisher gyűrű a corneában



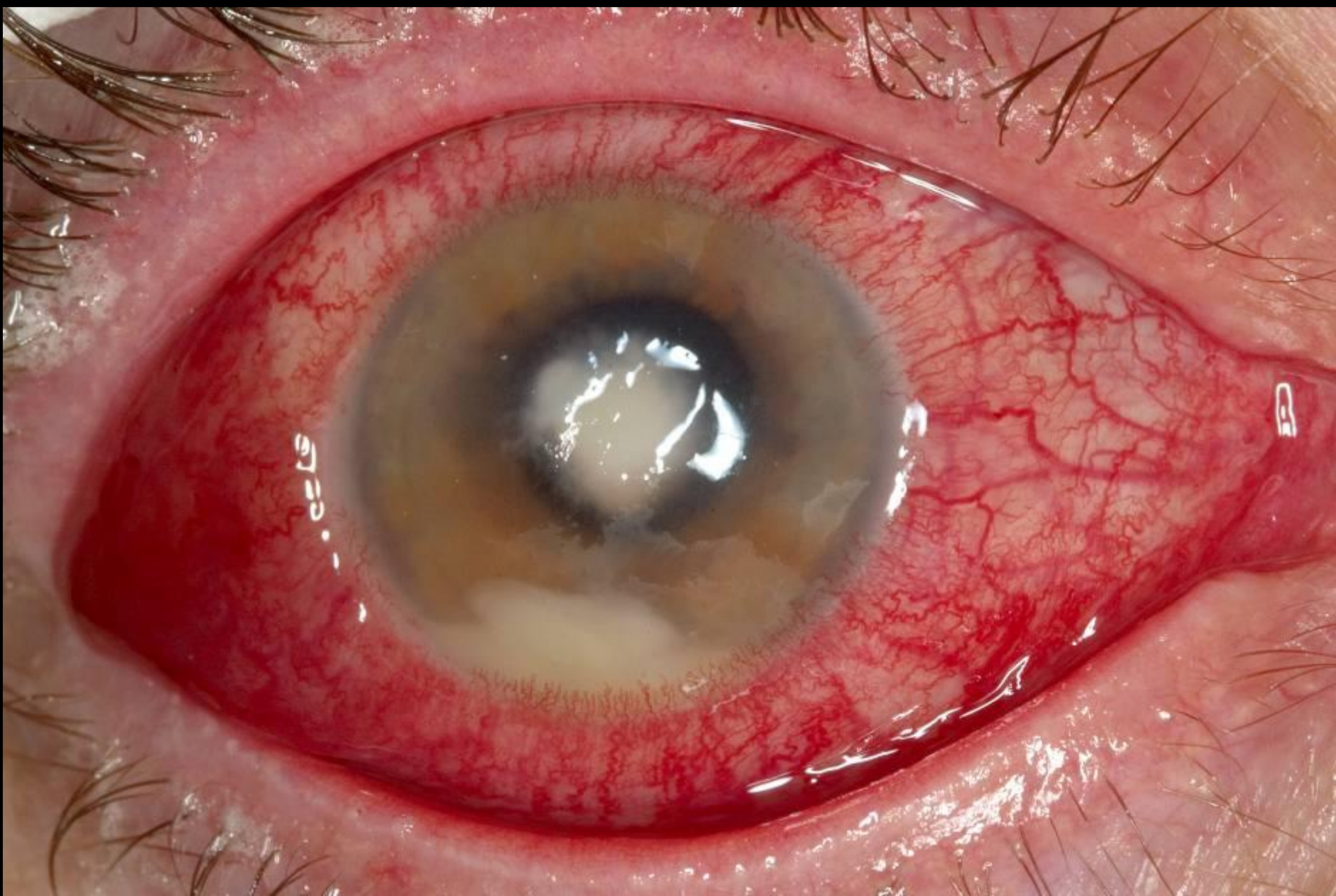
strabismus convergens



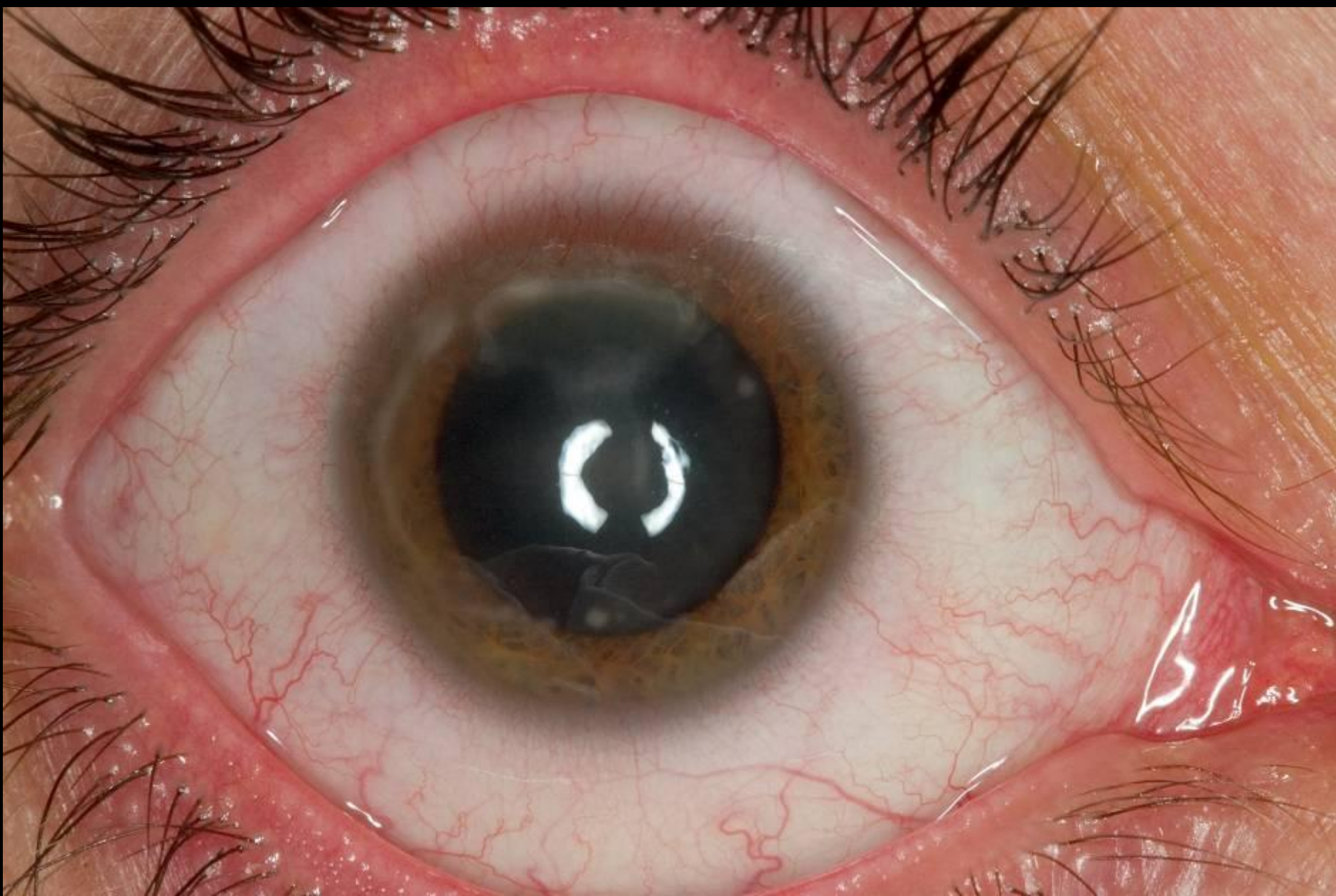
keratoprosthesis



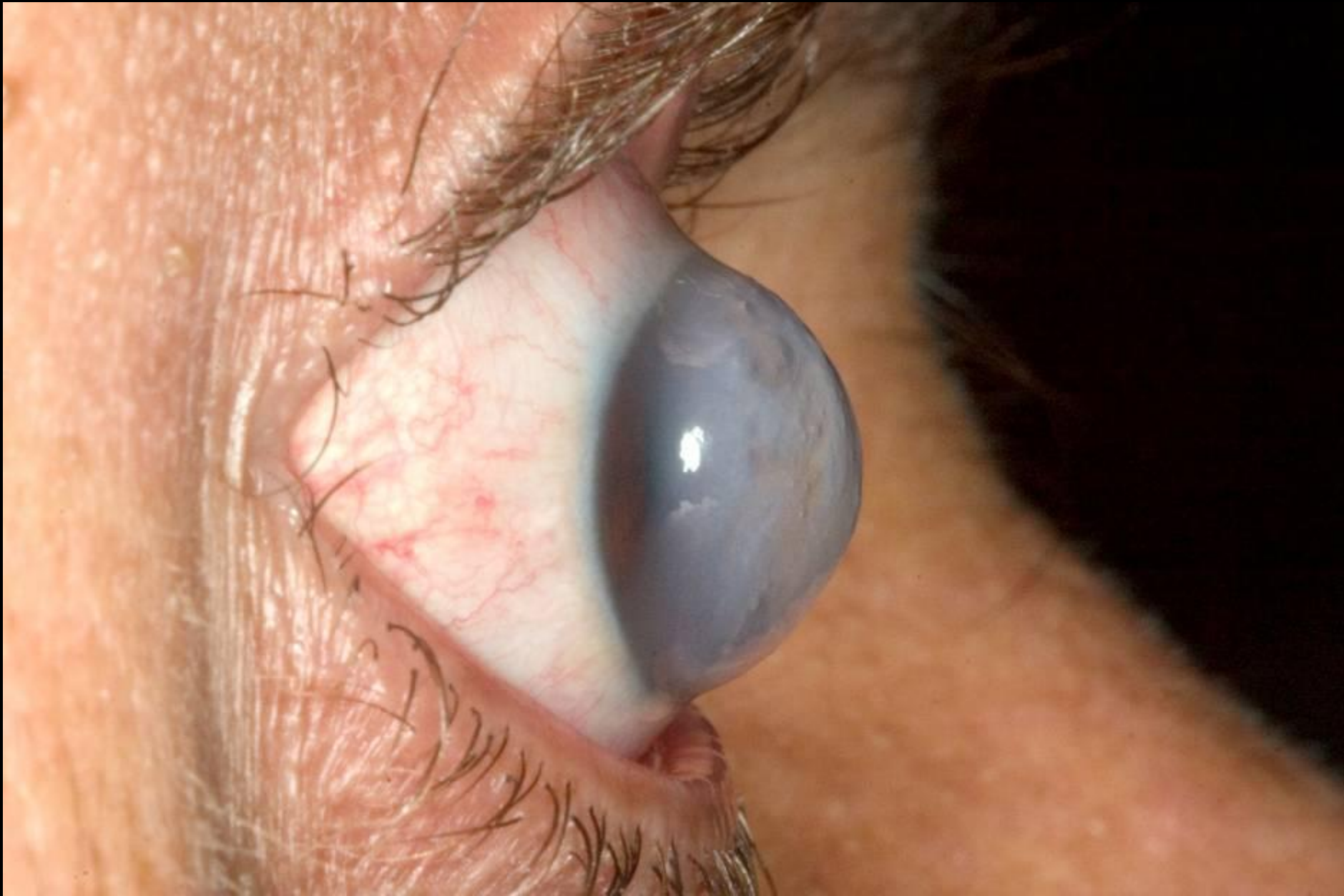keratitis dendritica fluorescein festéssel



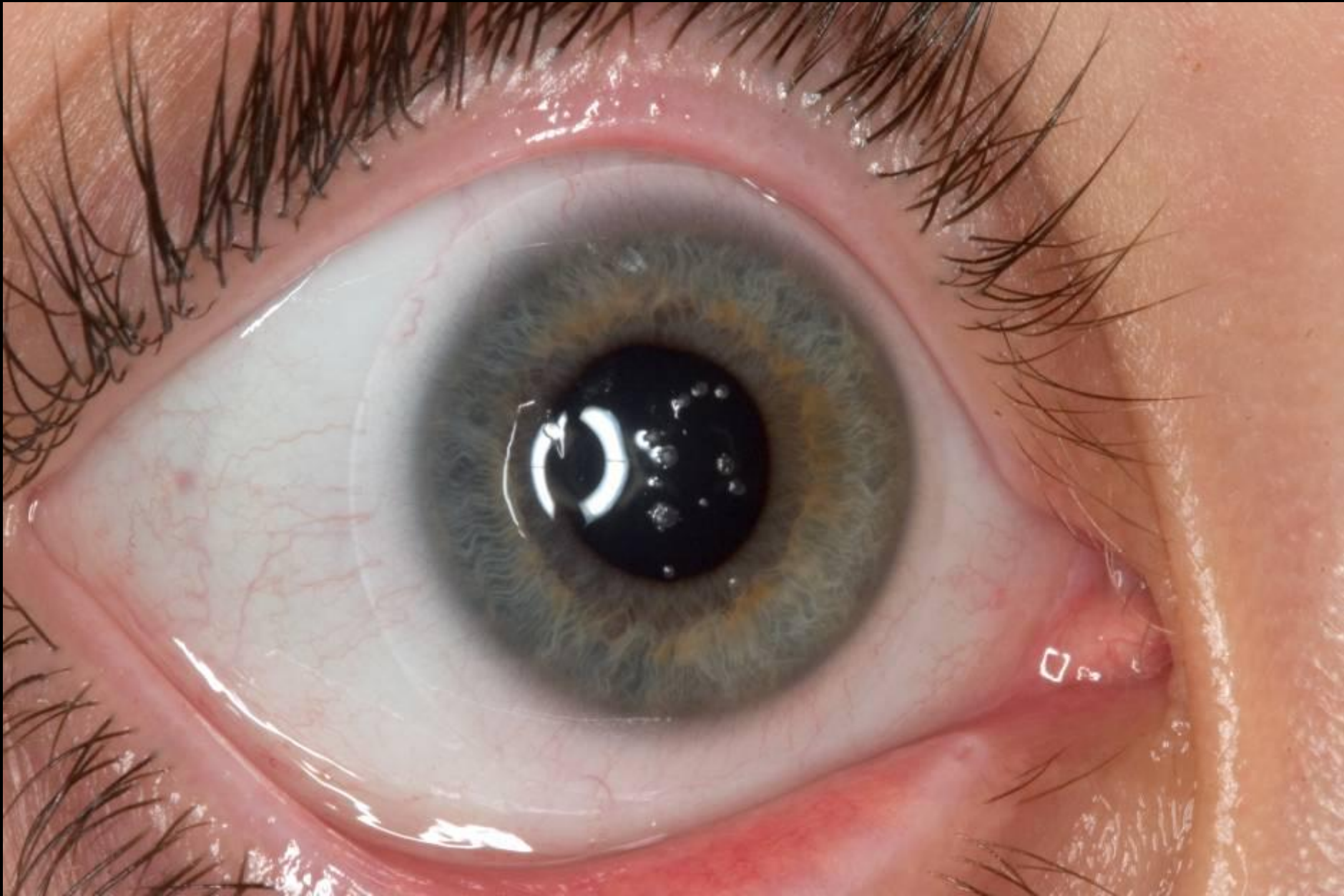keratitis cum hypopyo



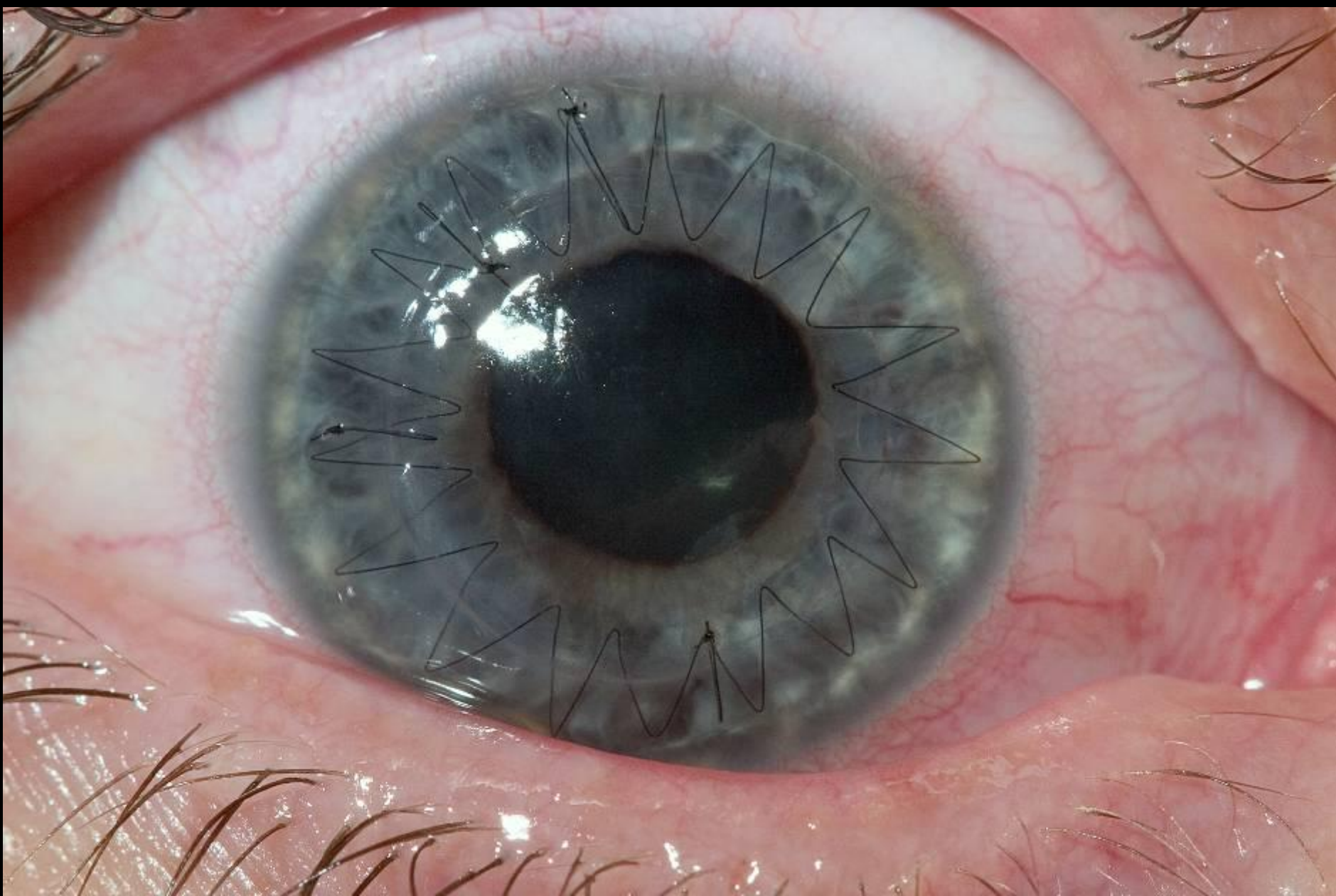
keratitis marginalis



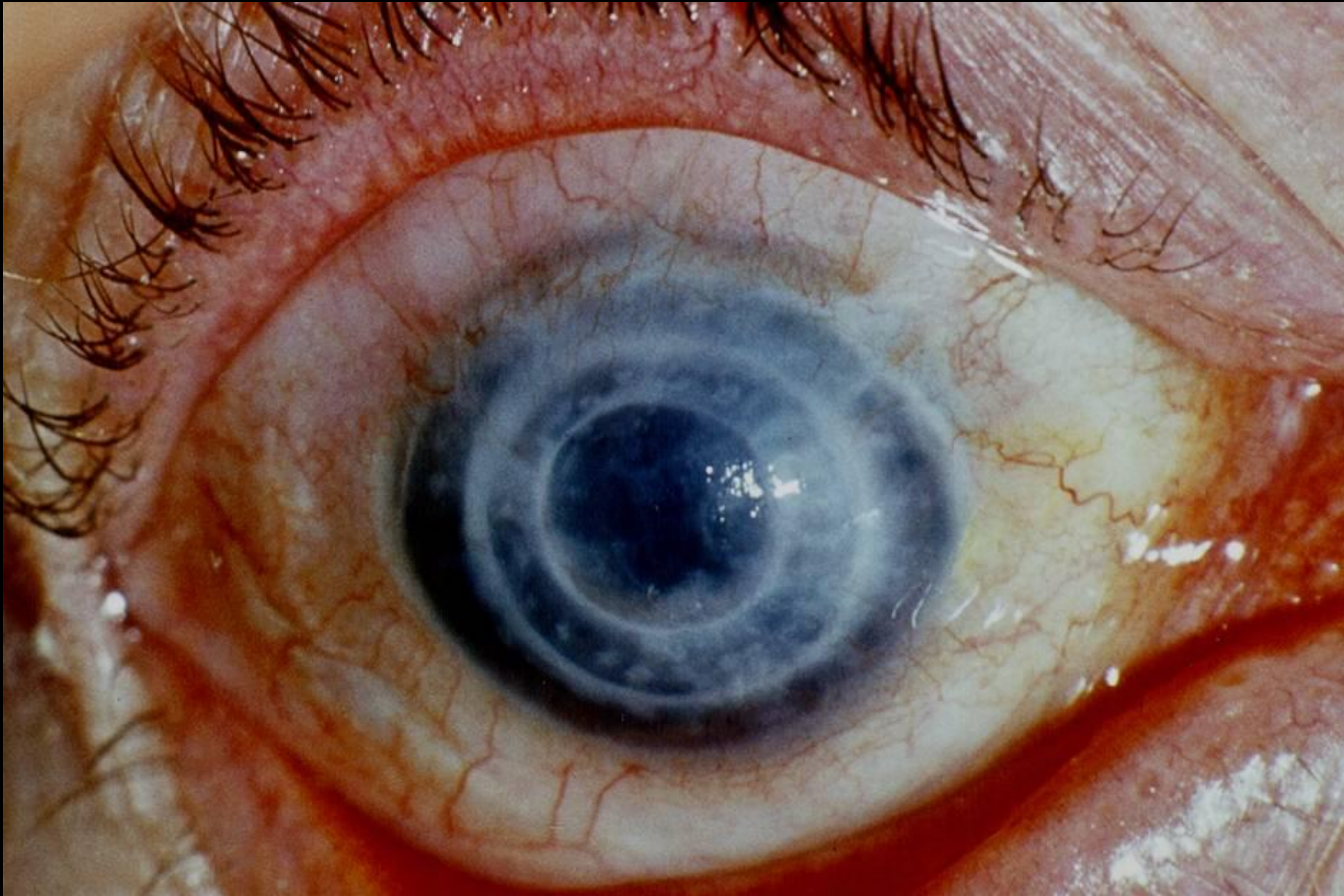
keratoconus acuta



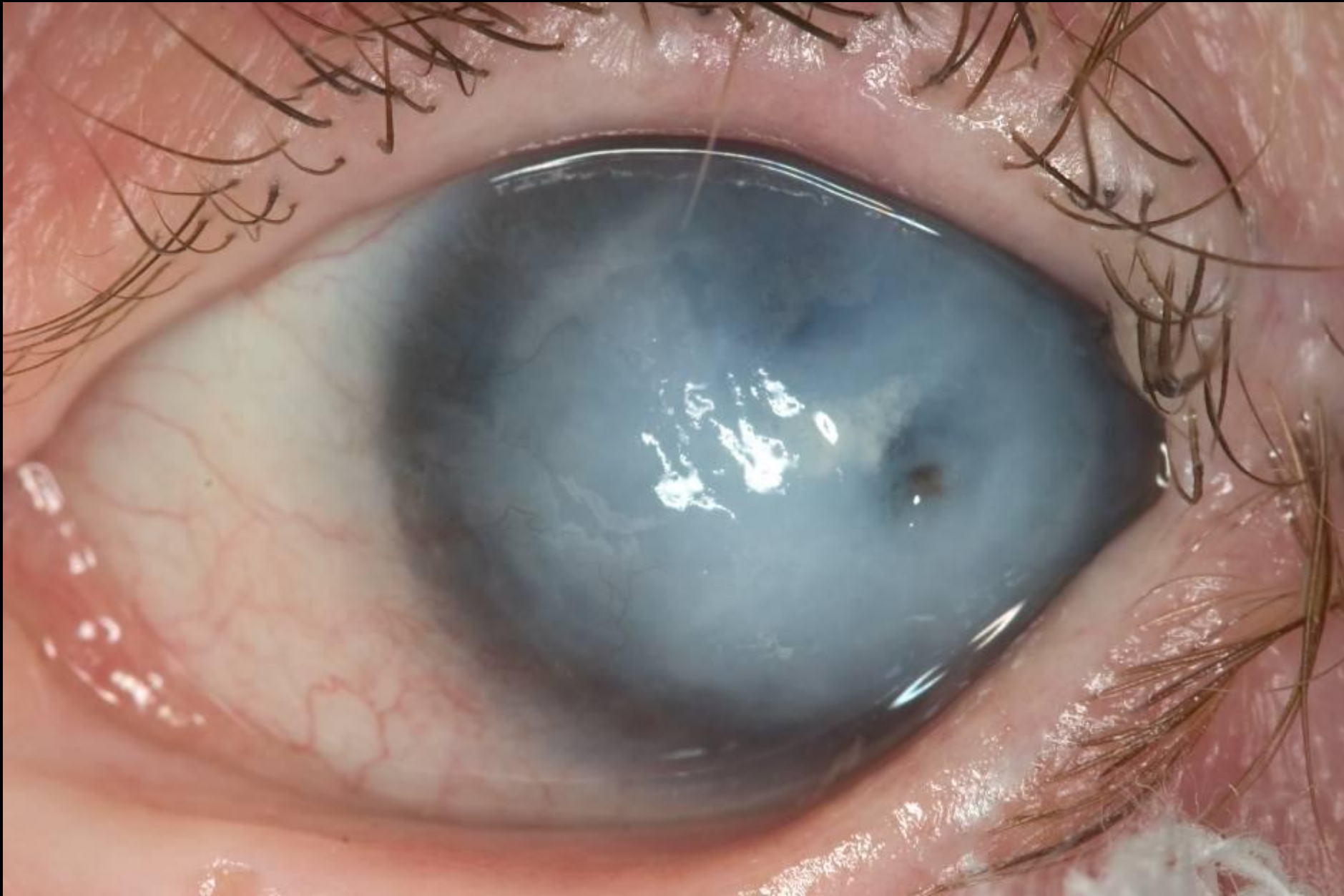felrakódások a kontaktlencsén



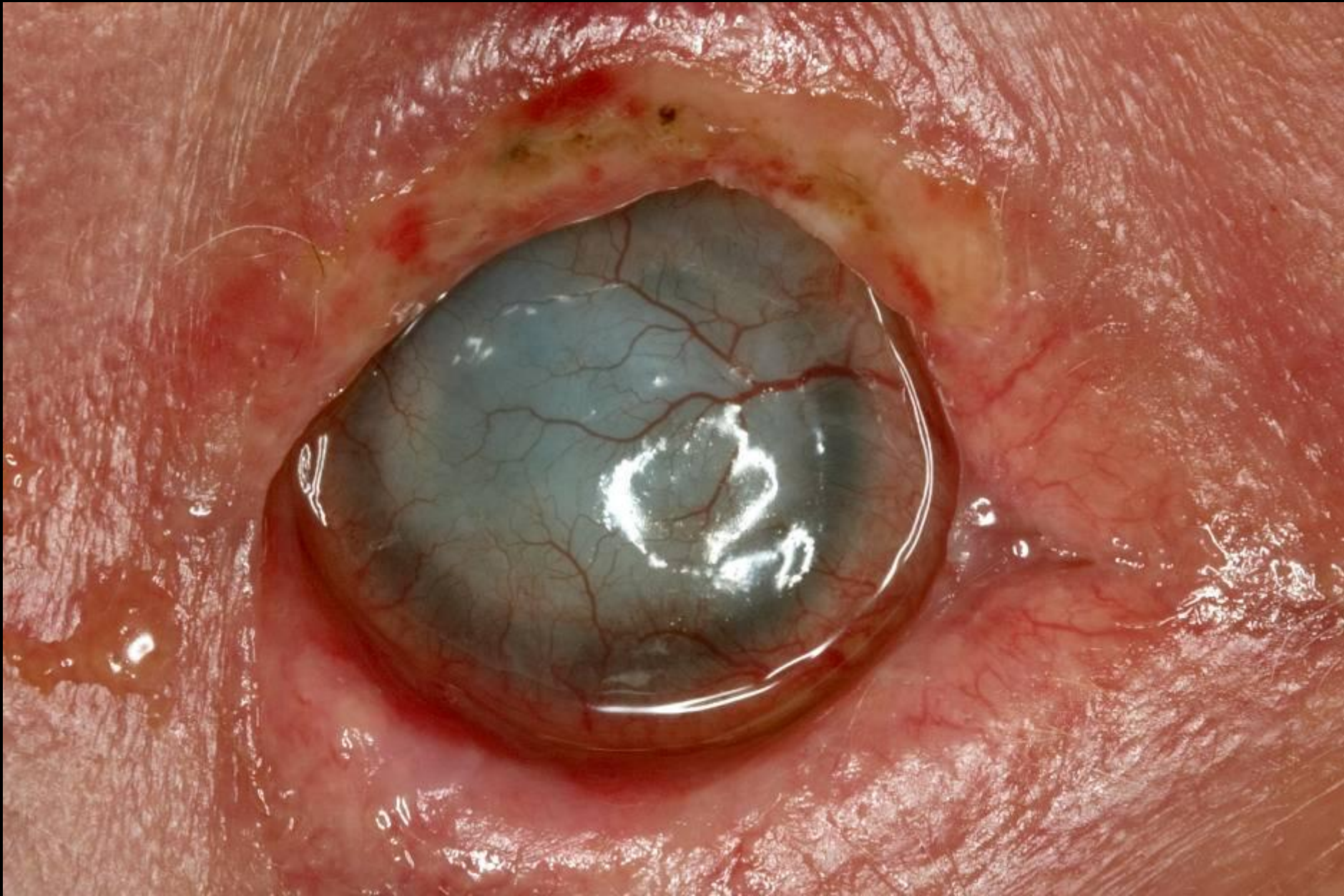status post keratoplasticam perforans



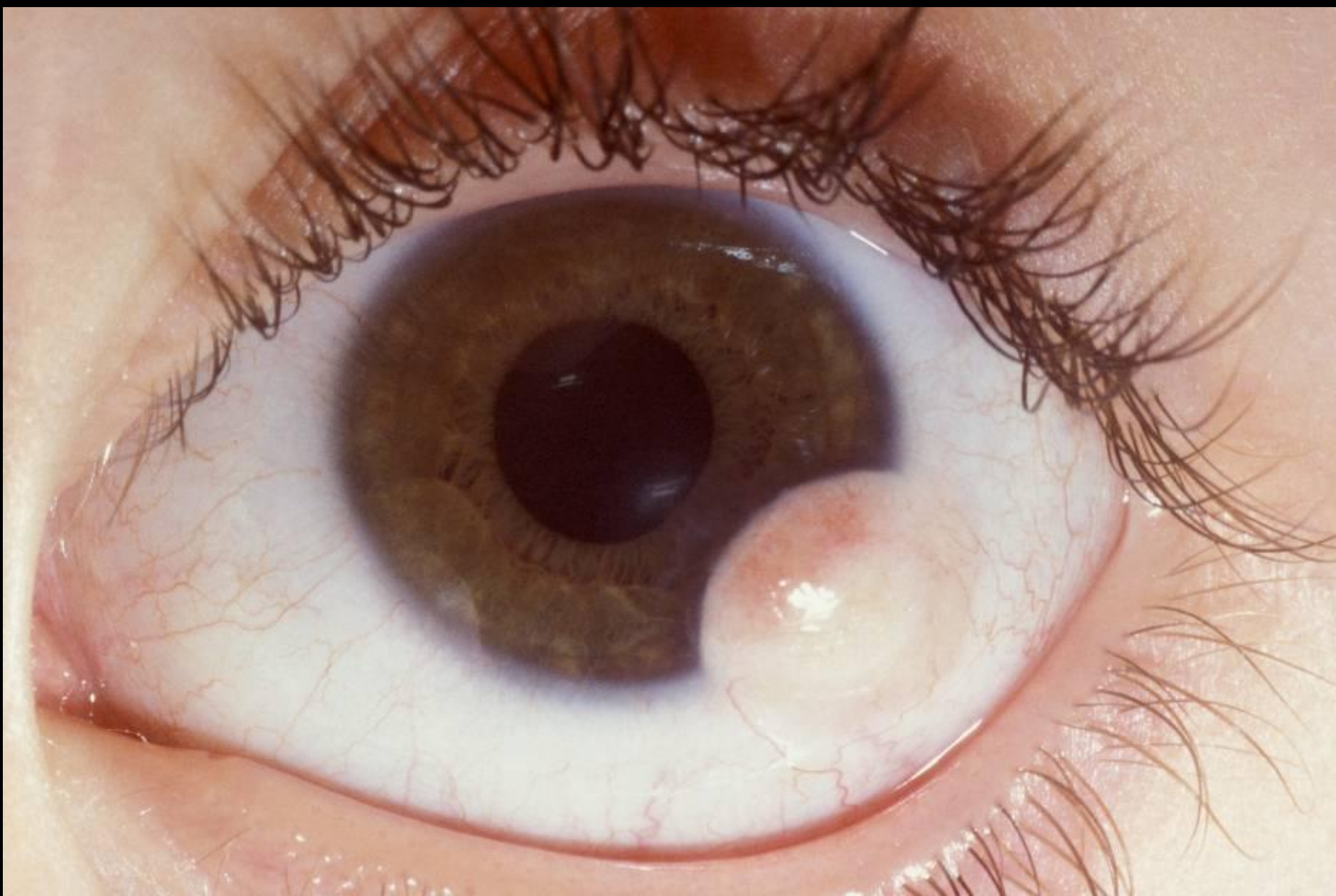status post rekeratoplasticam perforans



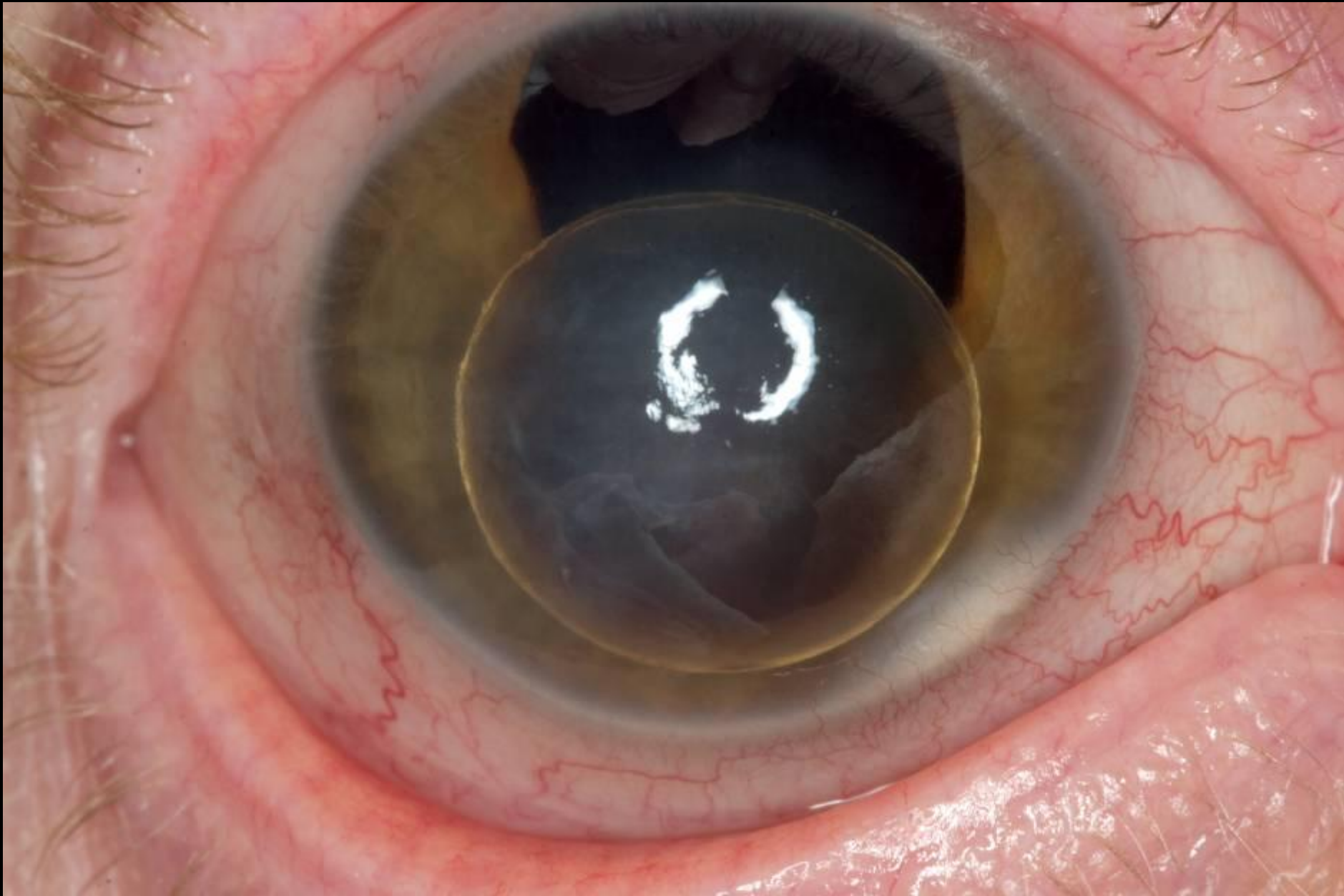
leucoma corneae et descemetokele



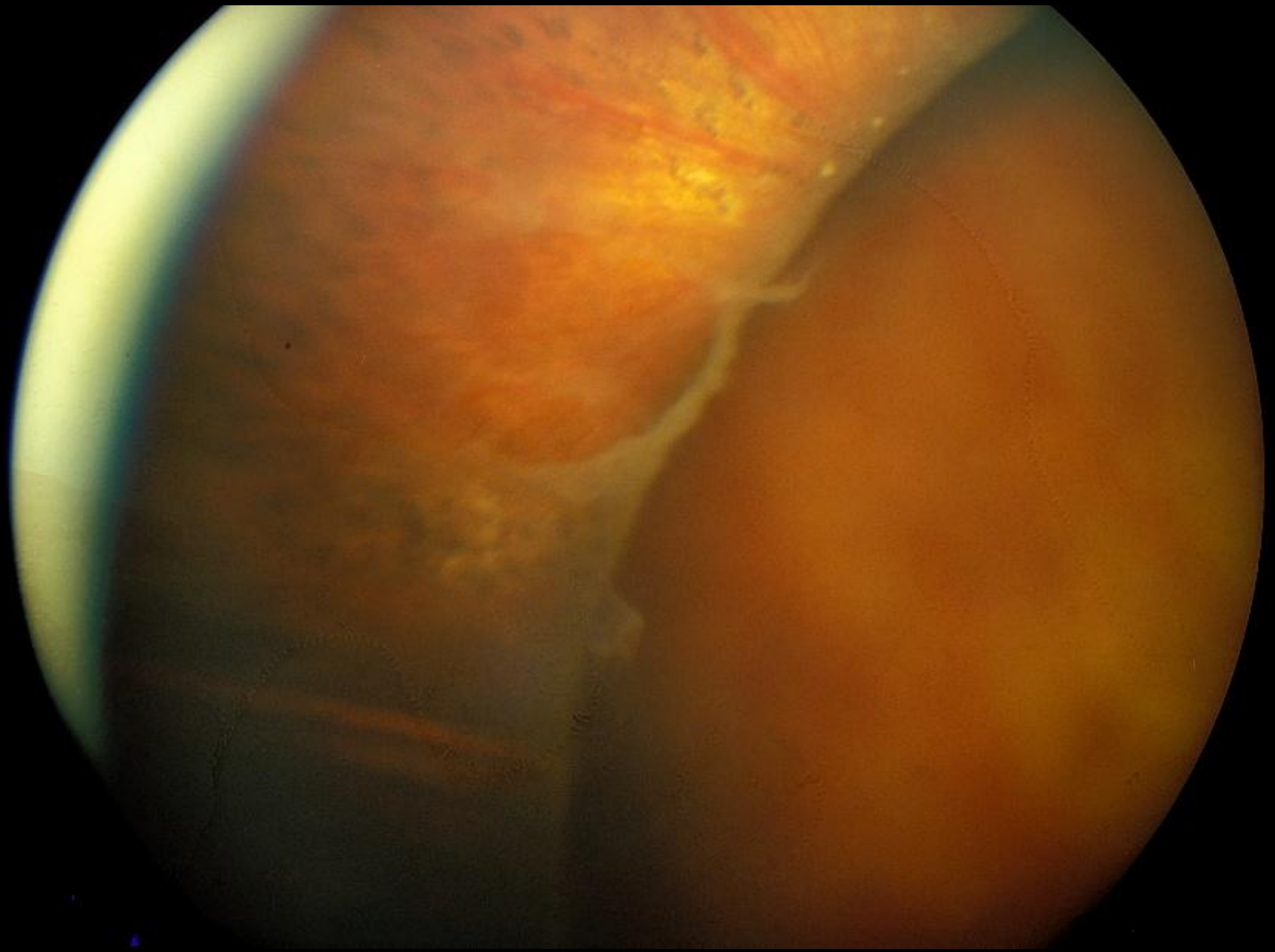
leucoma corneae vascularisata



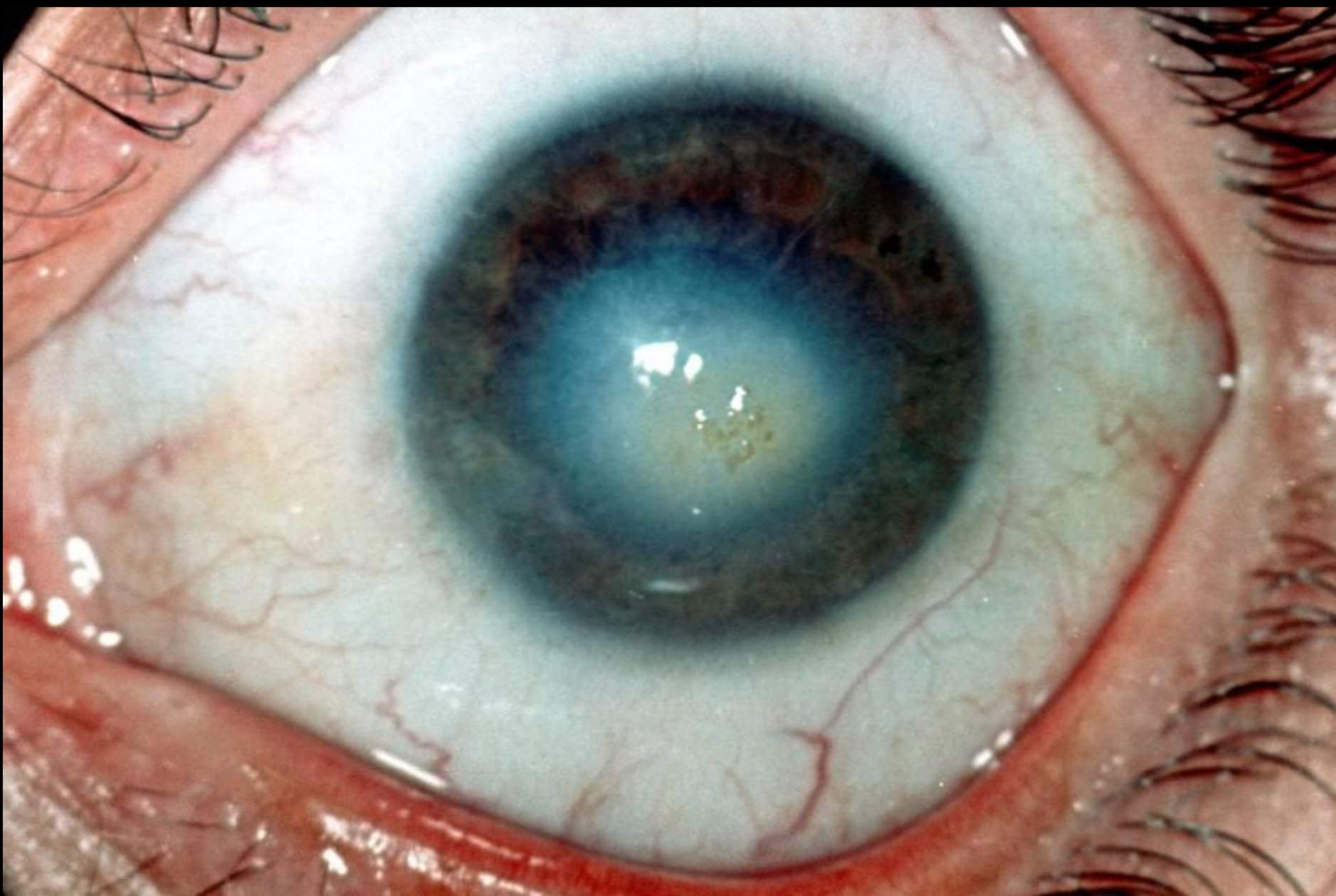
limbalis dermoid



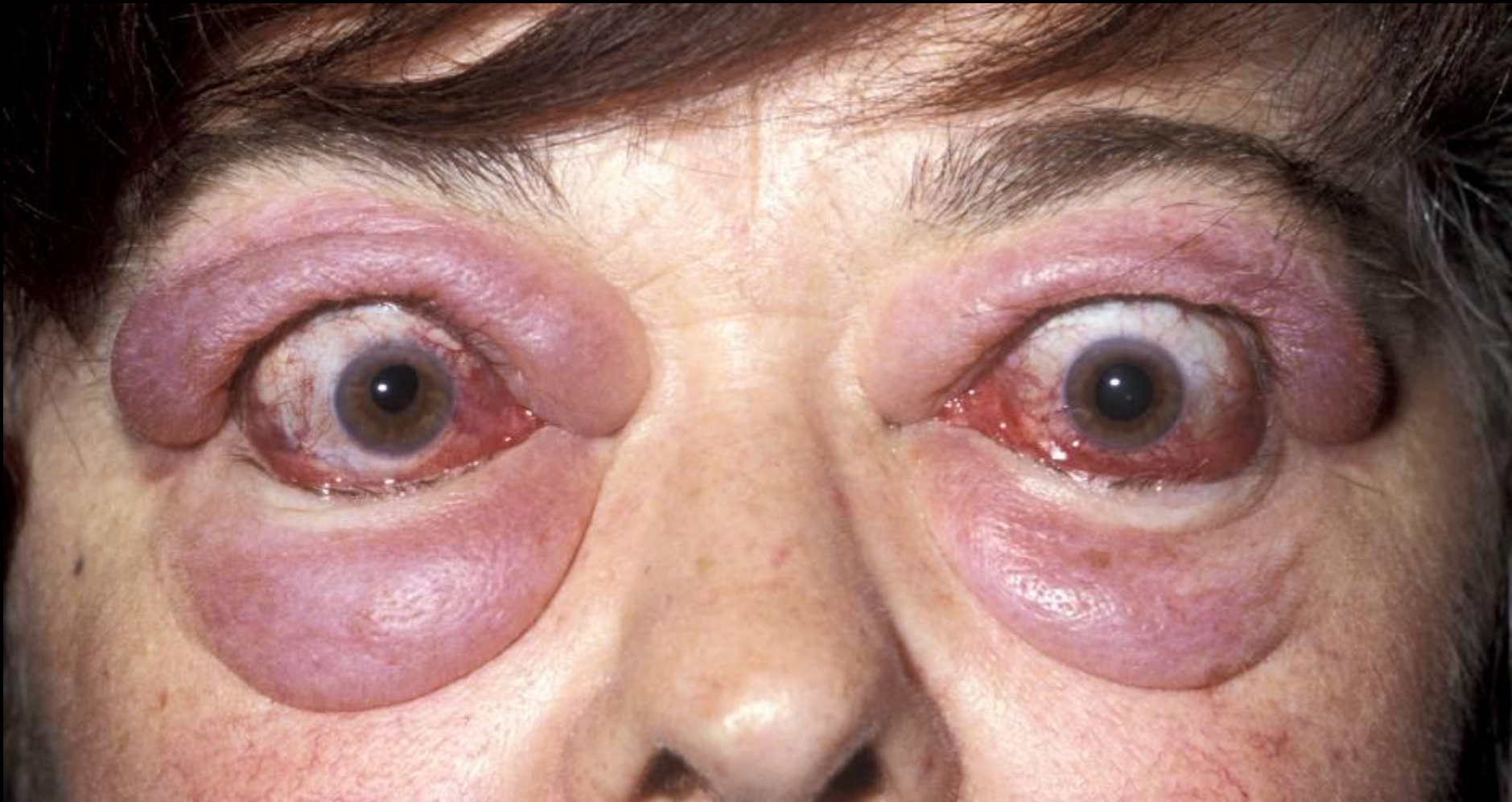luxatio lentis in cameram anterioris et coloboma iridis



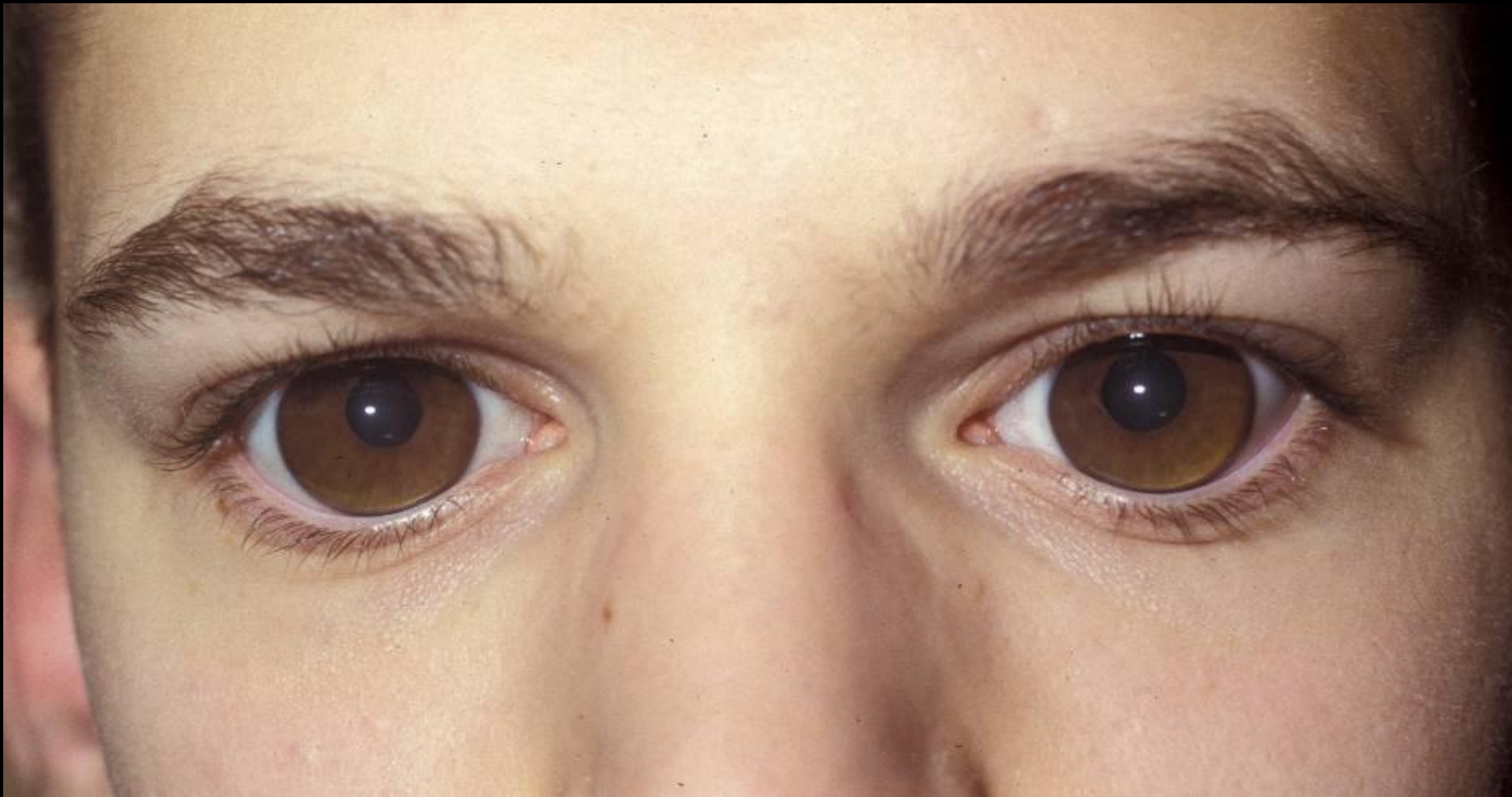foramen retinae et cerclage bulbi



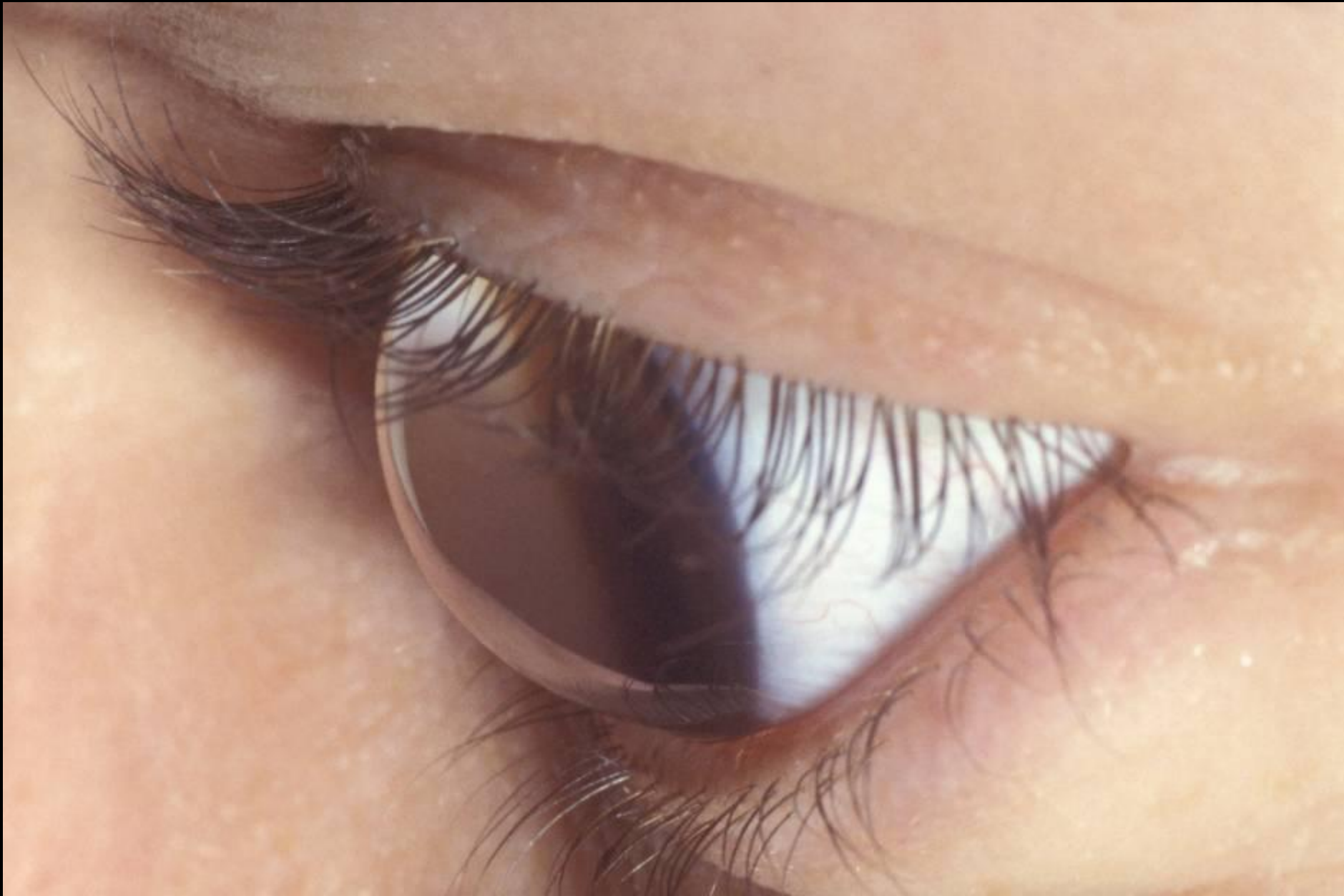macula corneae



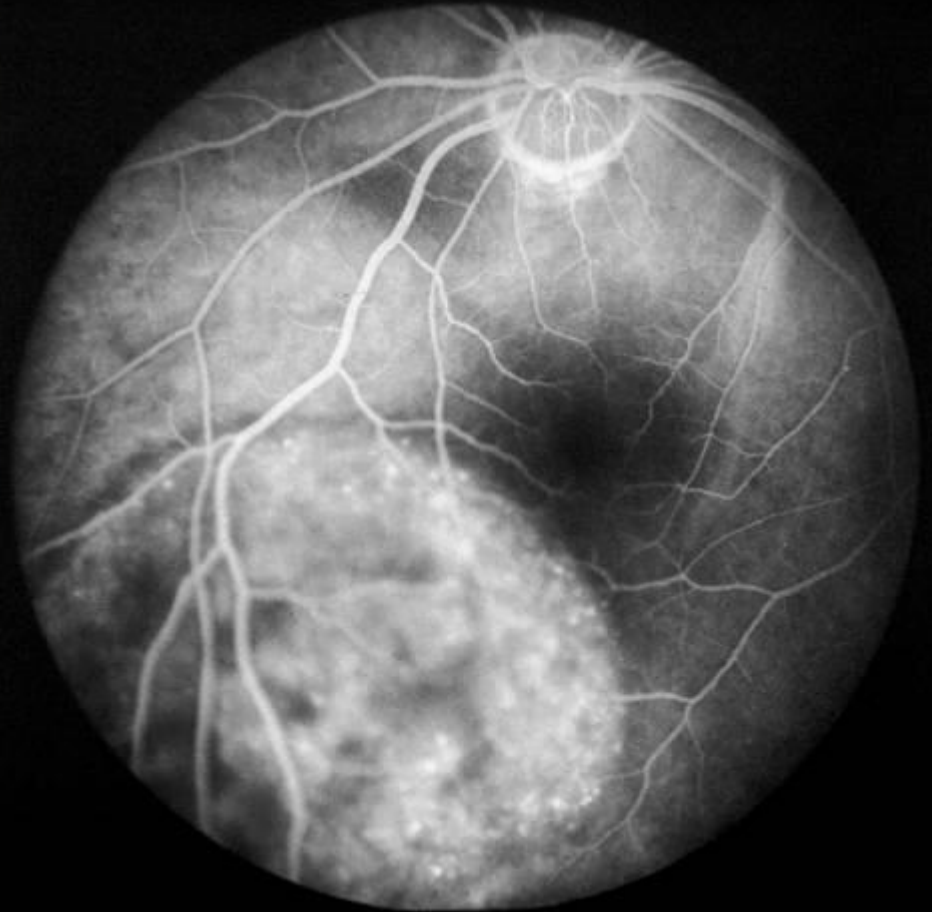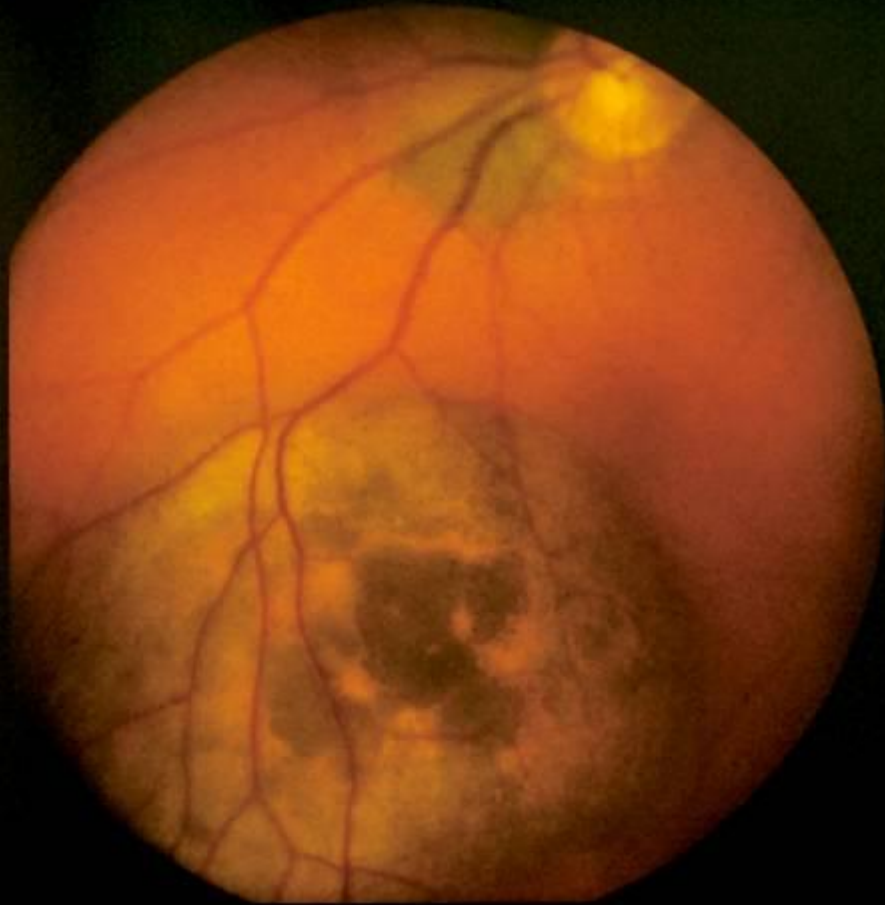
exophthalmus maligna



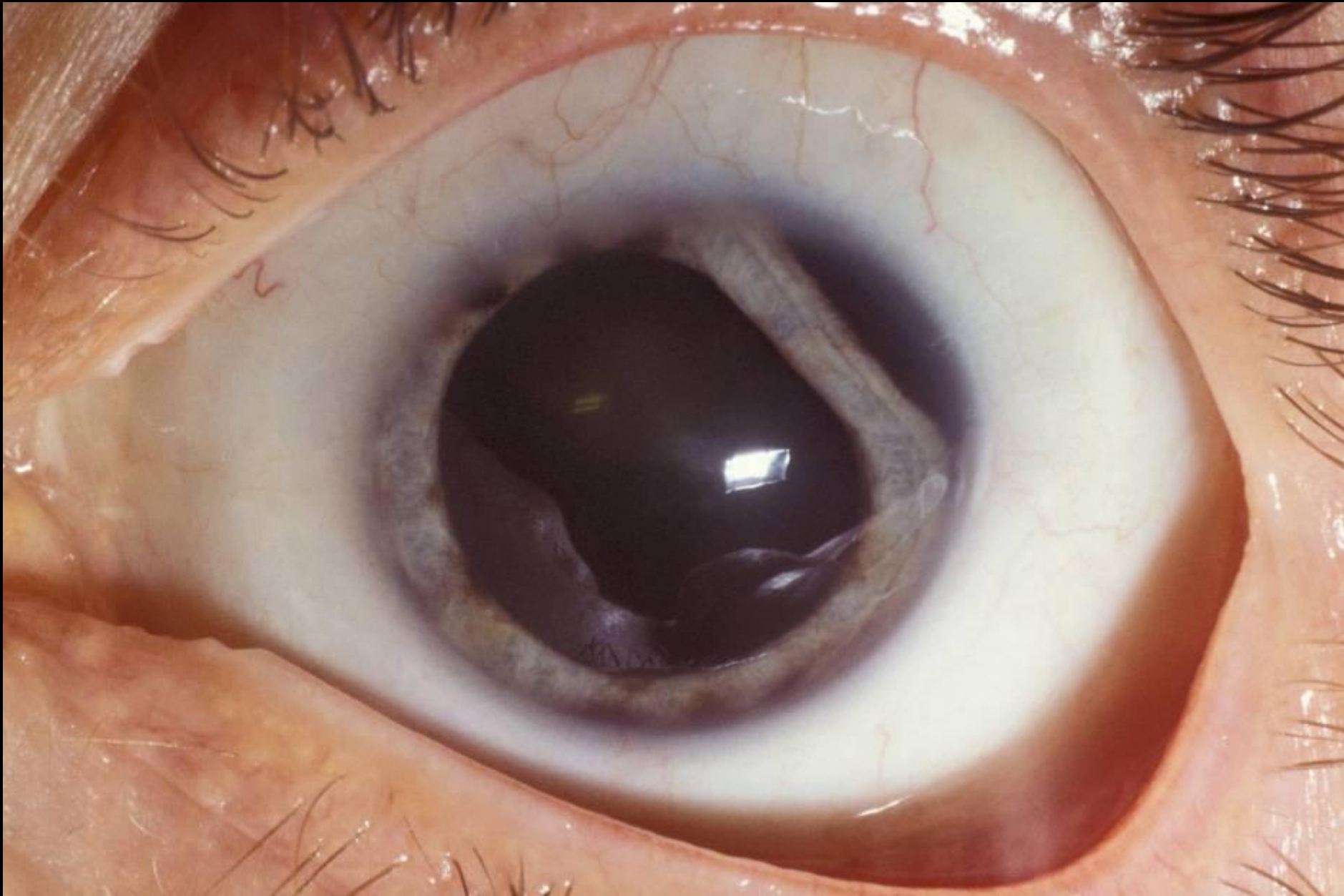
megalocornea



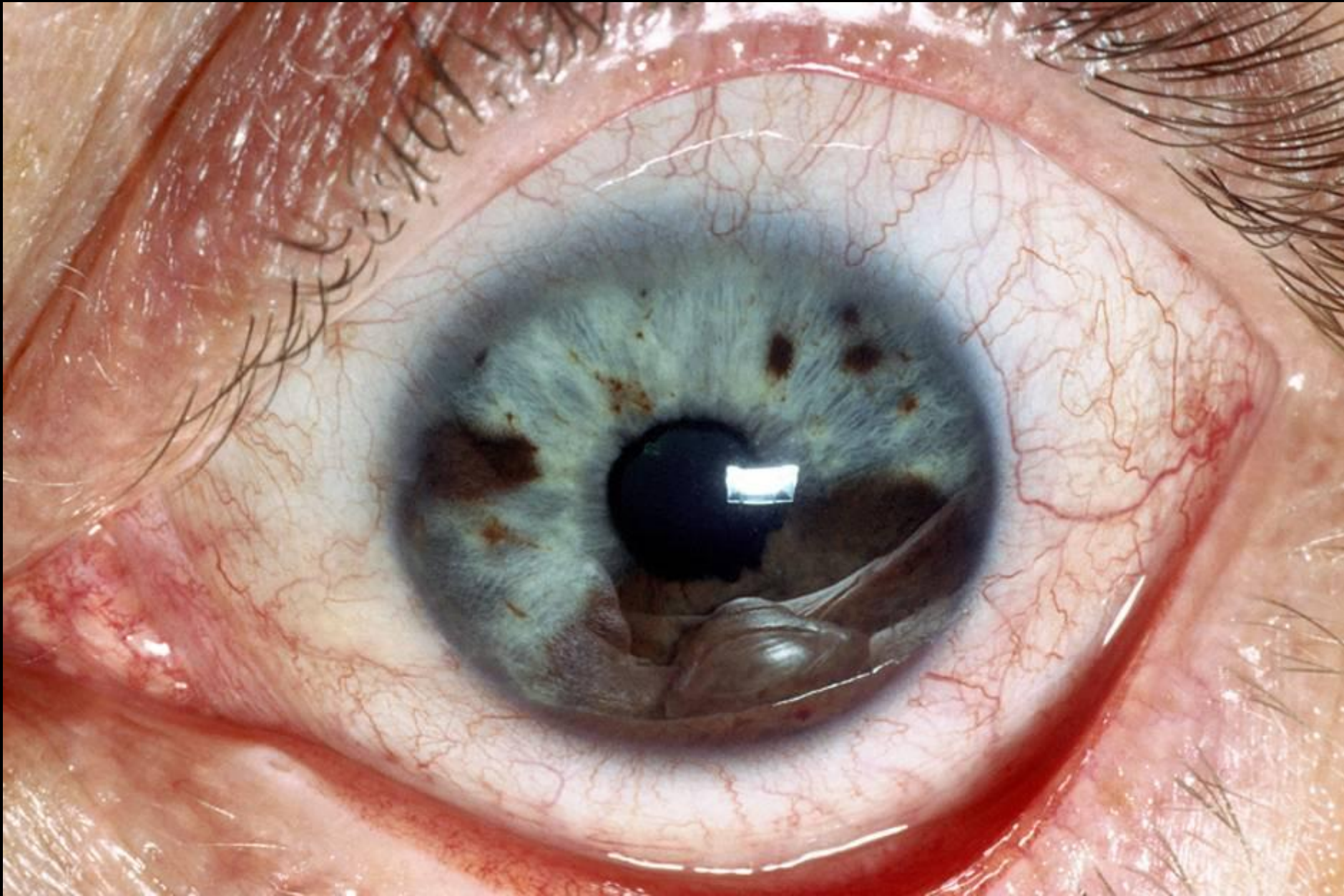
megalocornea oldalnézetből



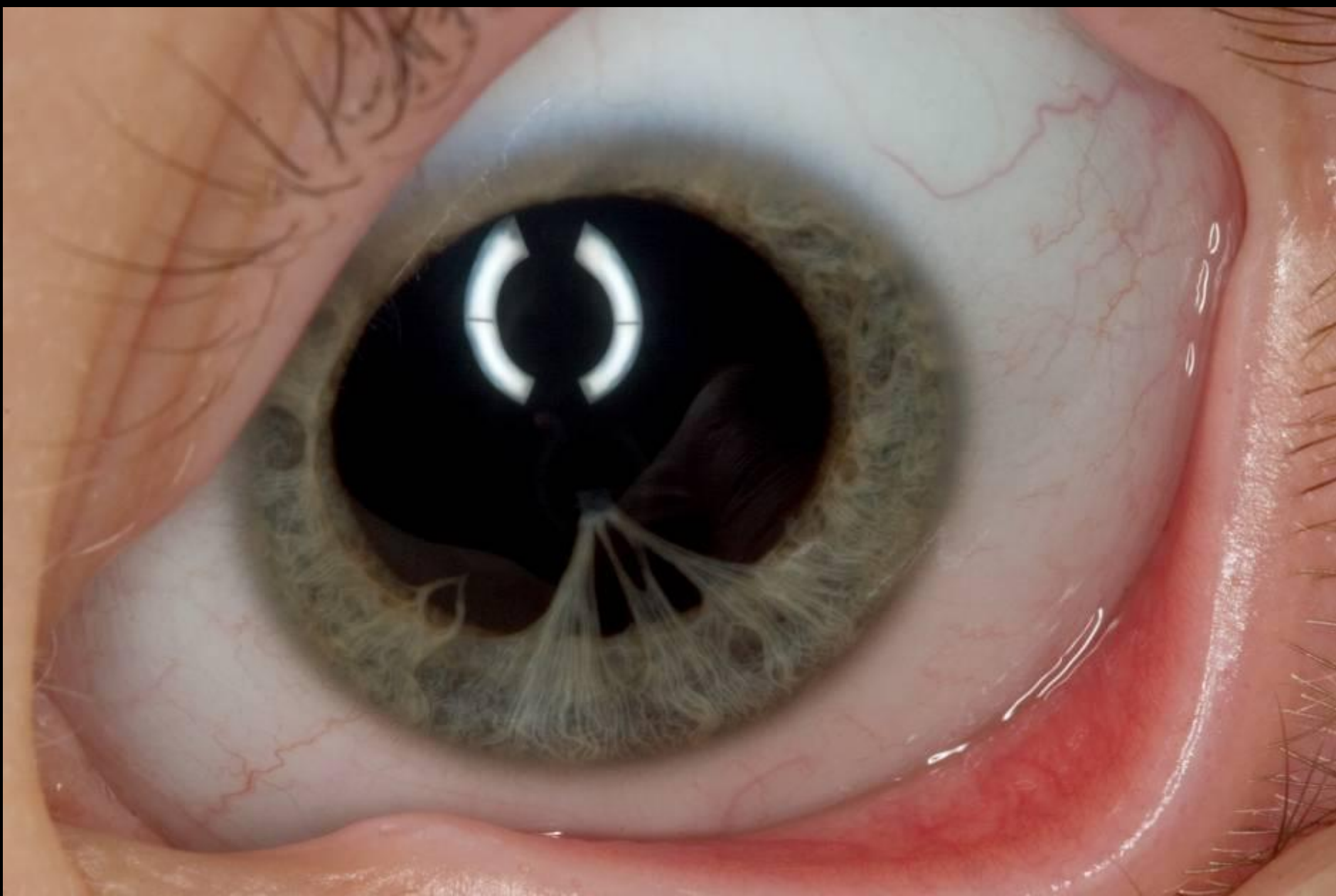**melanoma malignum chorioideae et naevus chorioideae együtt,
jobbra a fluorescein angiográfiás felvétel**



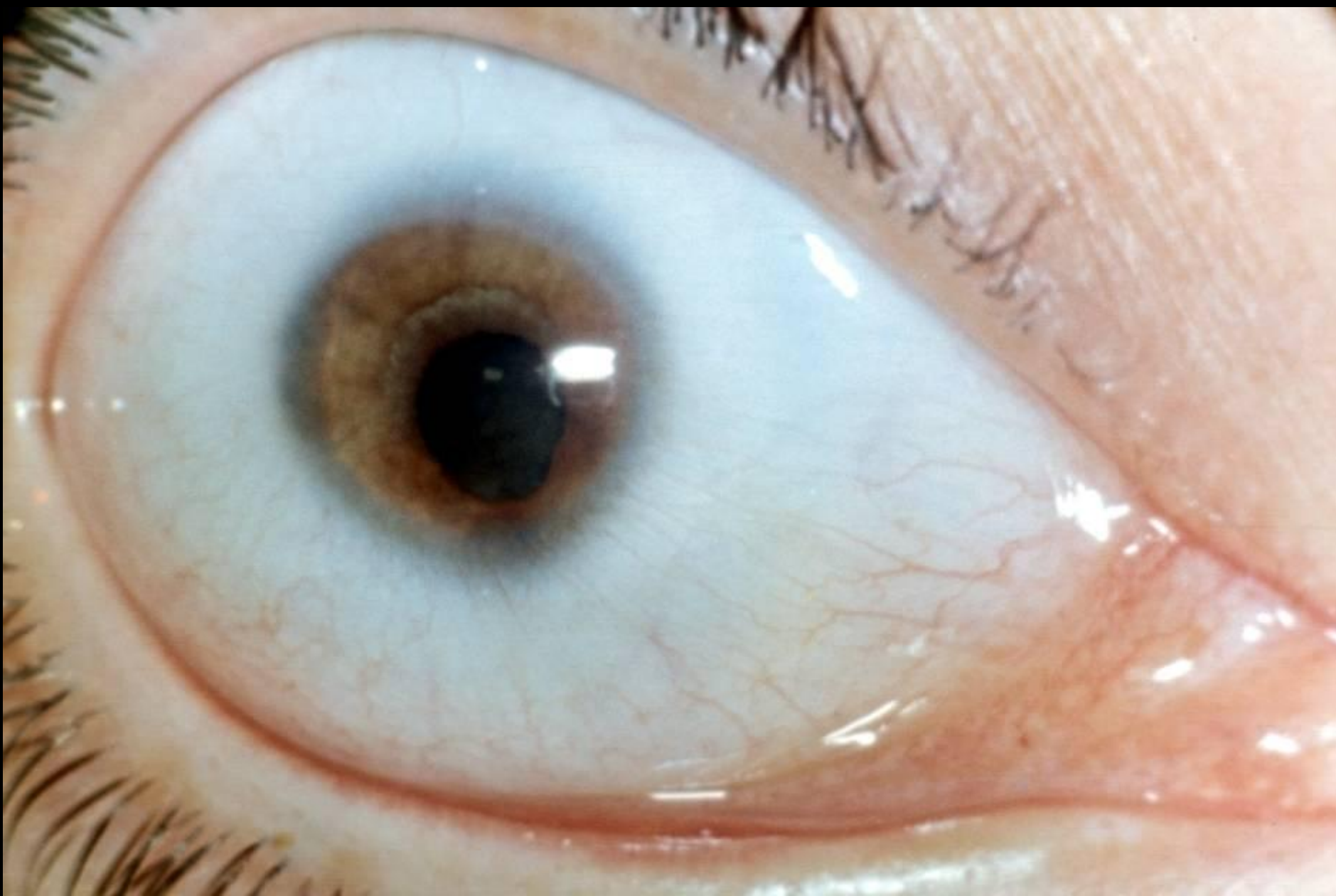melanoma malignum corporis ciliareae



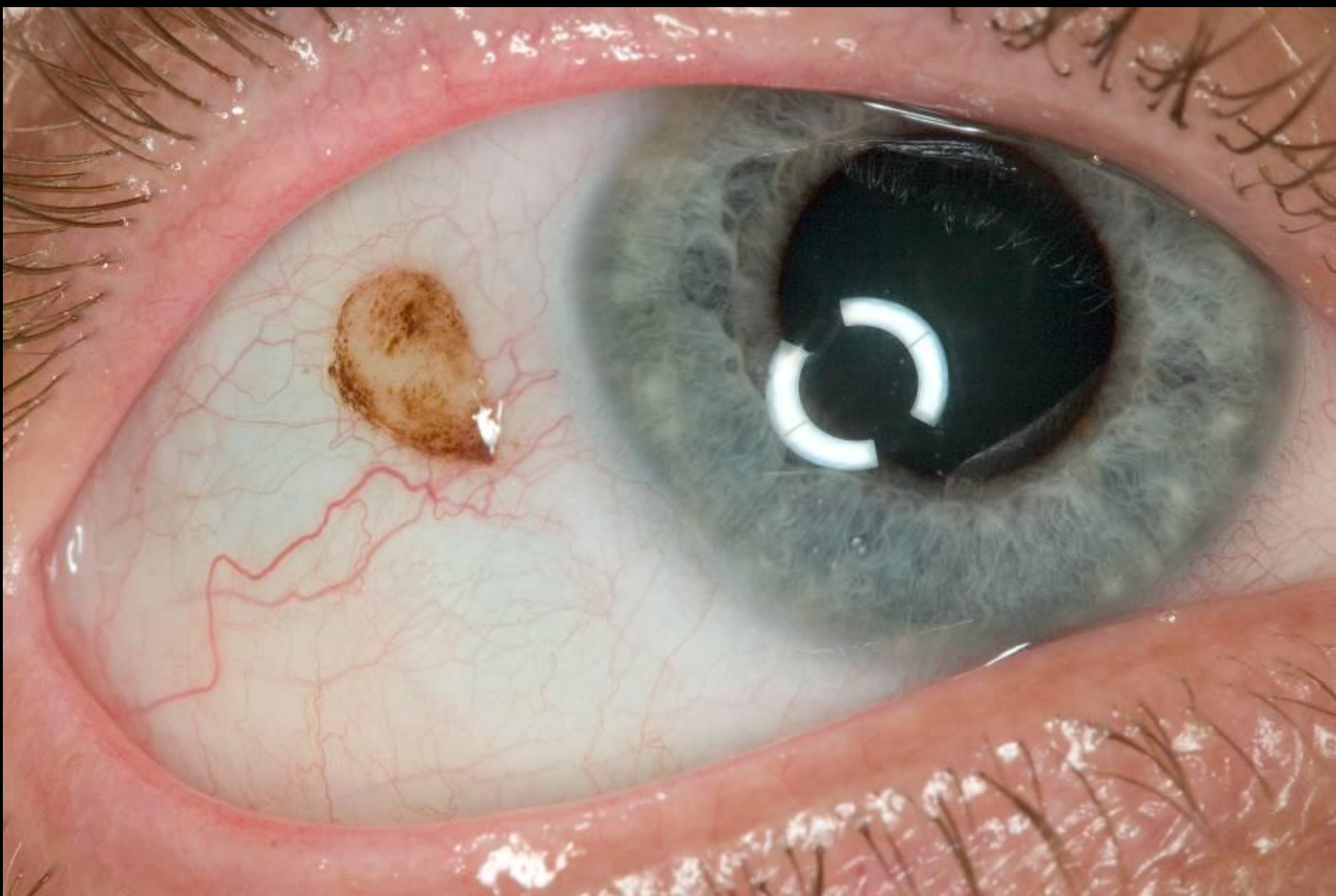melanoma malignum iridis



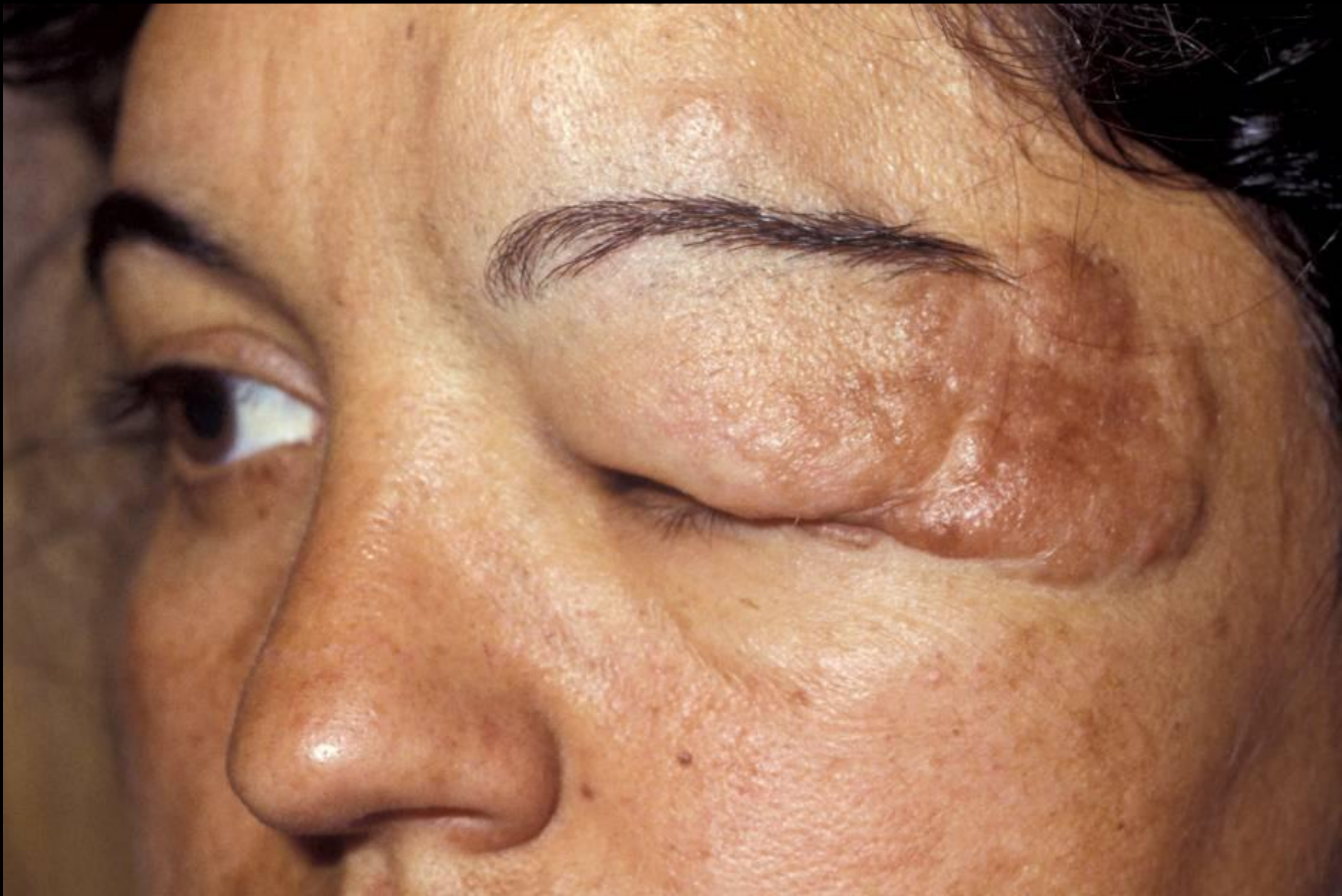membrana pupillaris persistens



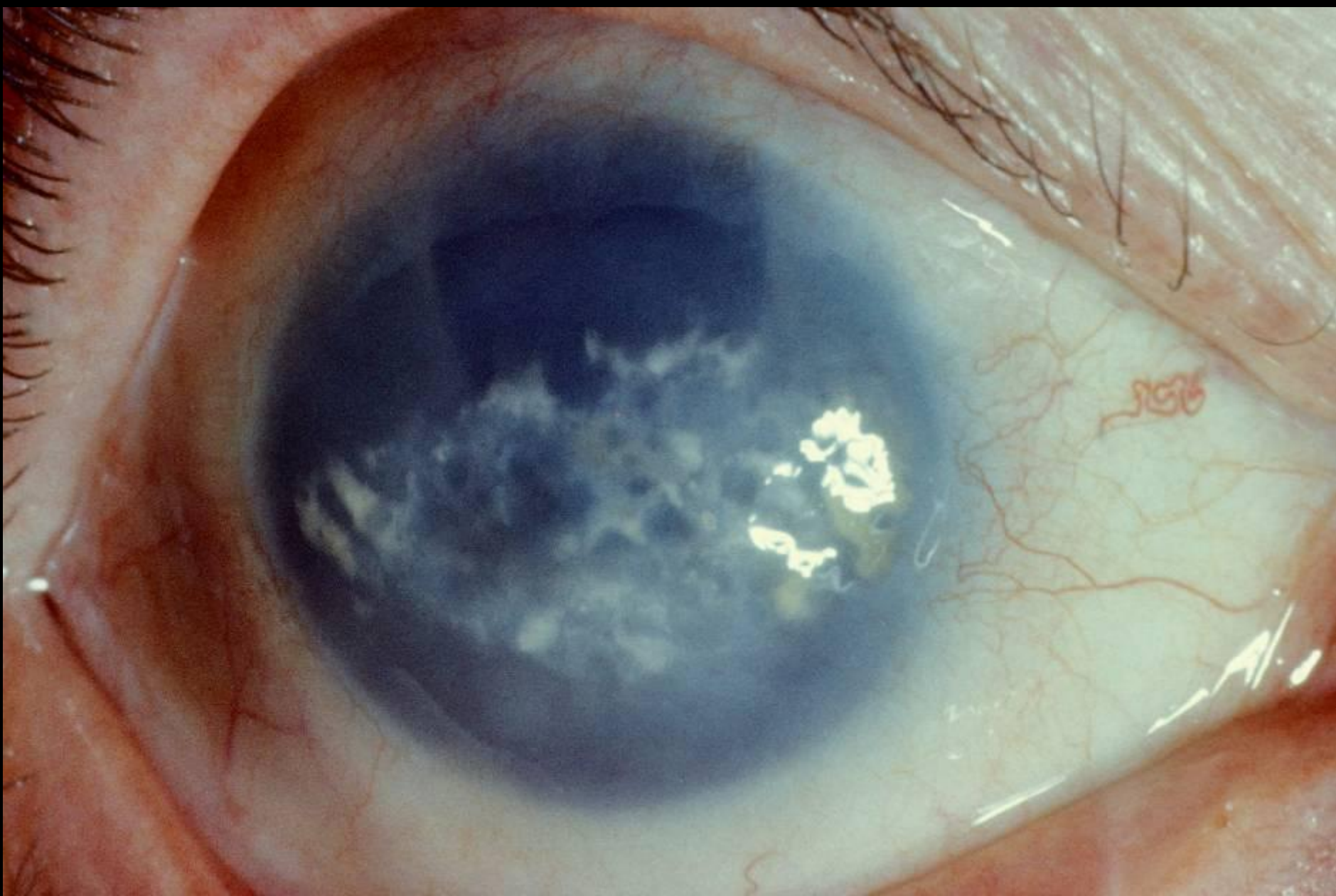
microcornea



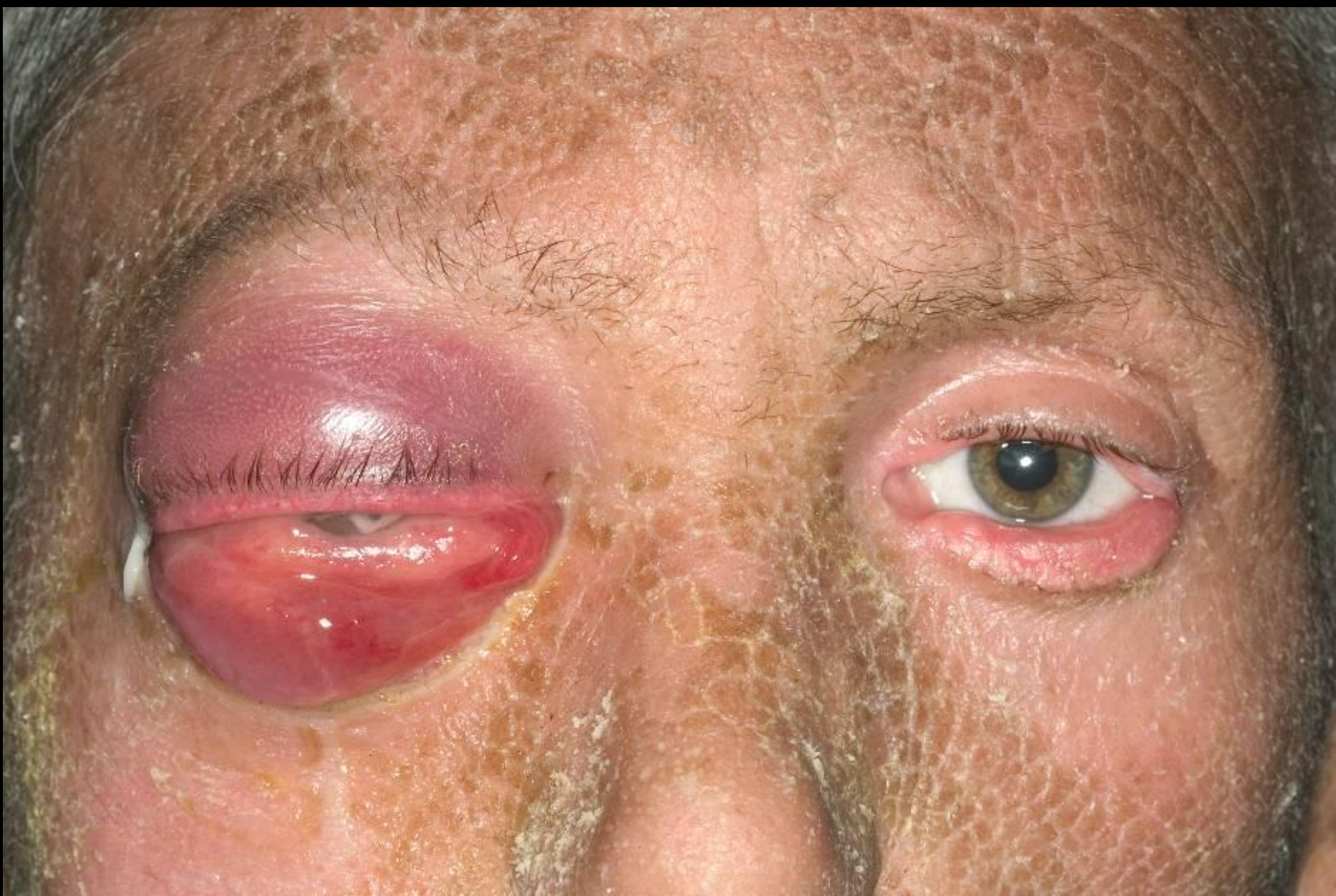naevus conjunctivae



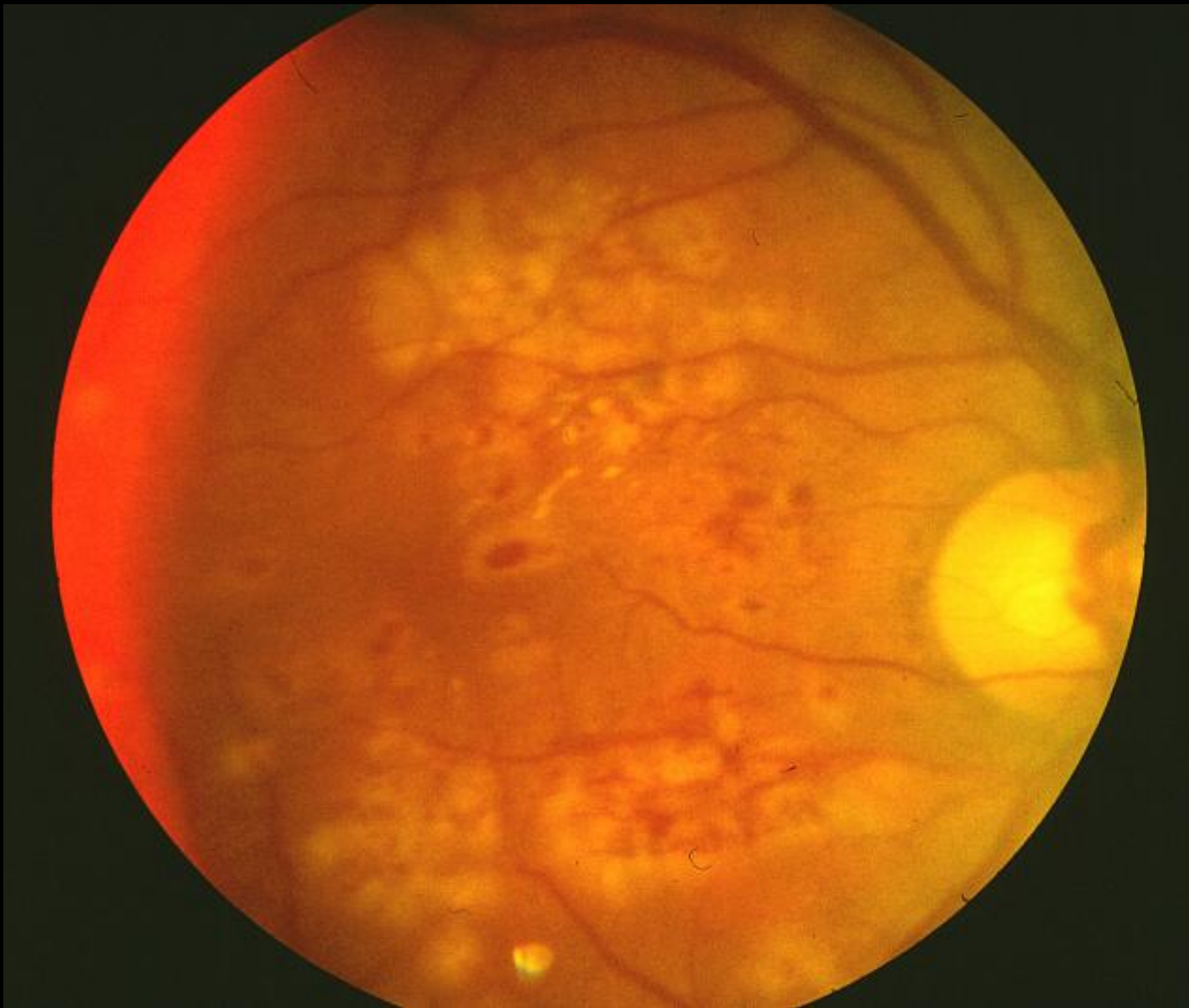
neurofibromatosis benigna



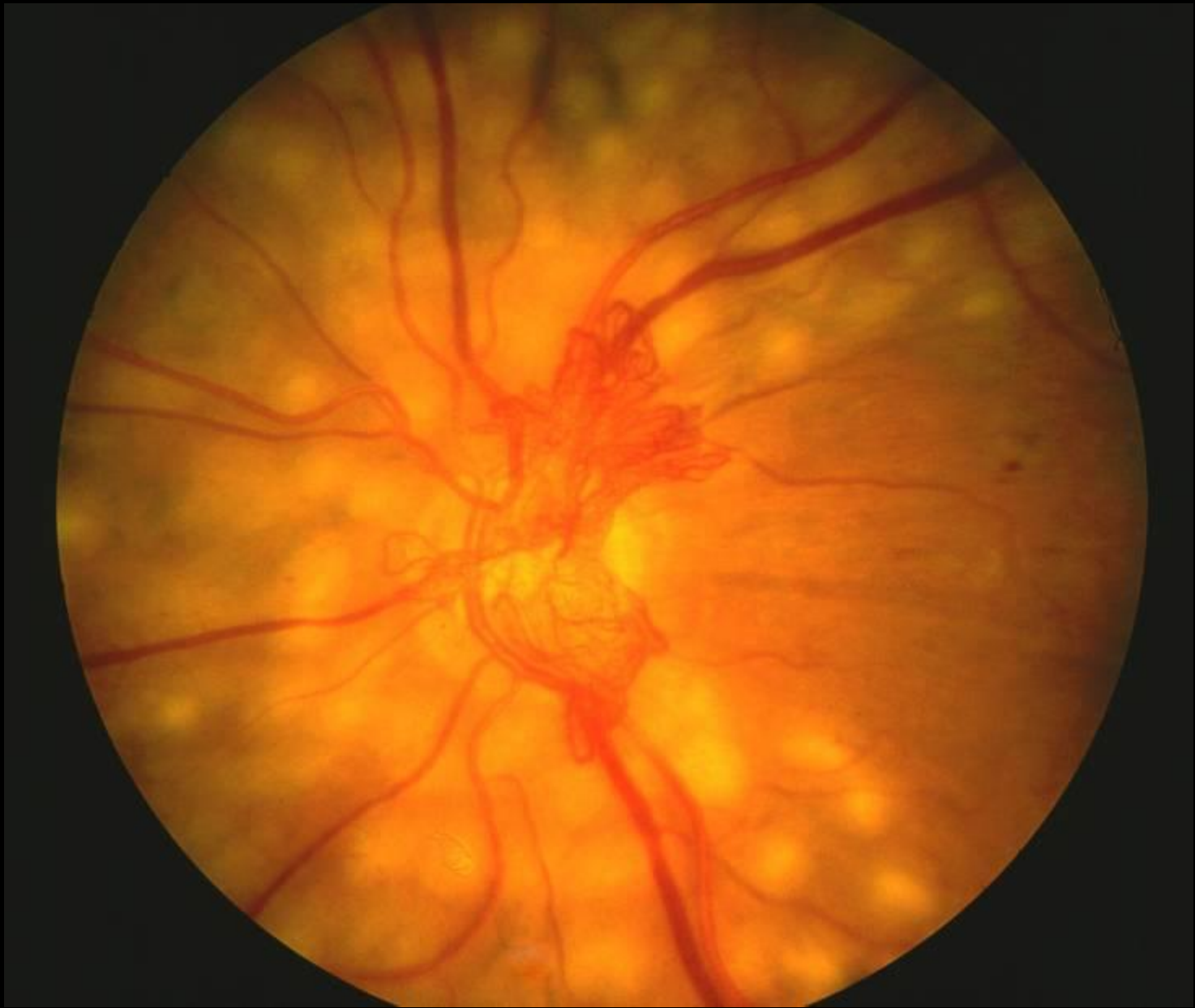opacitas zonularis corneae



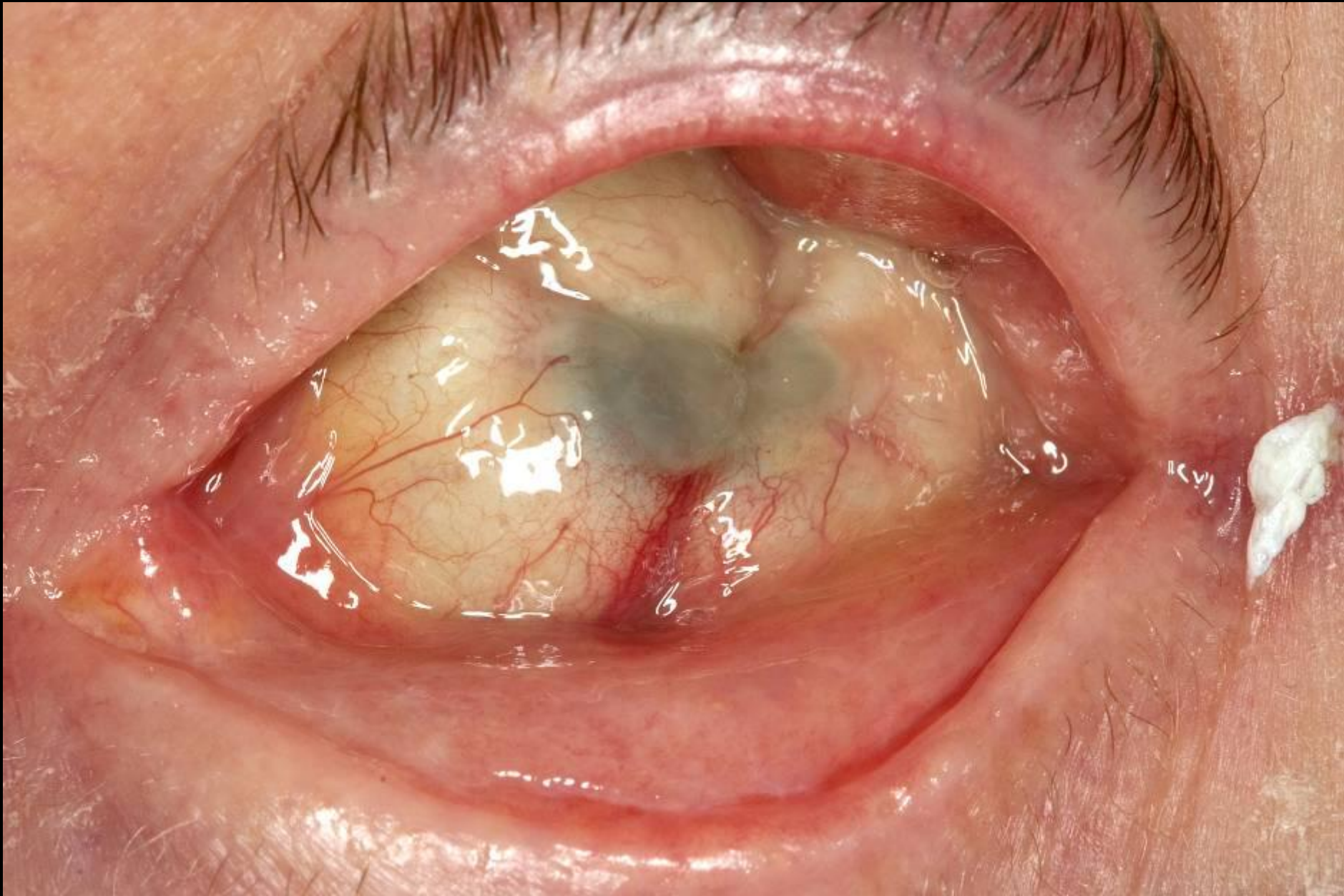panophthalmitis



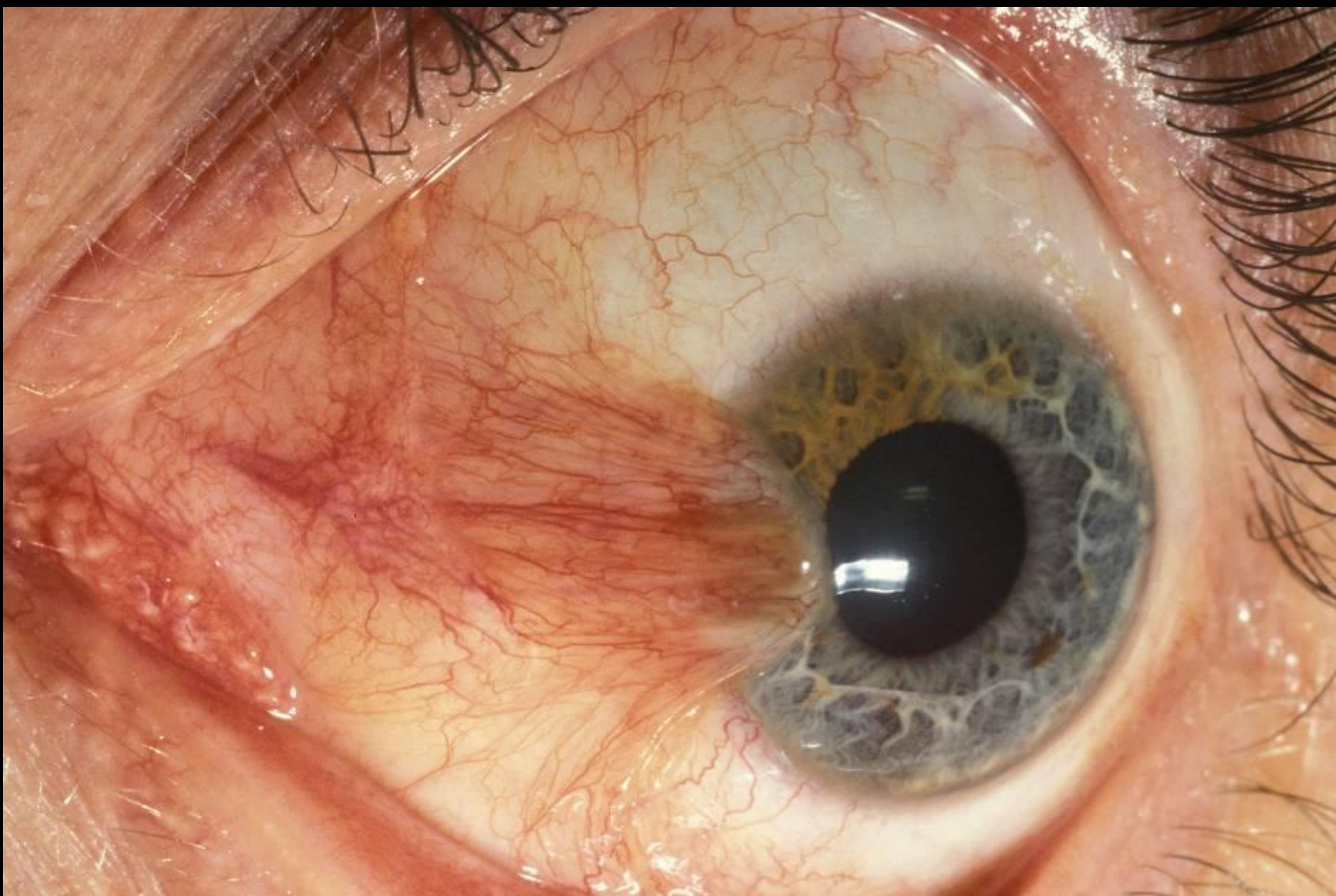
focalis lézerkezelés diabeteses háttér retinopathiában



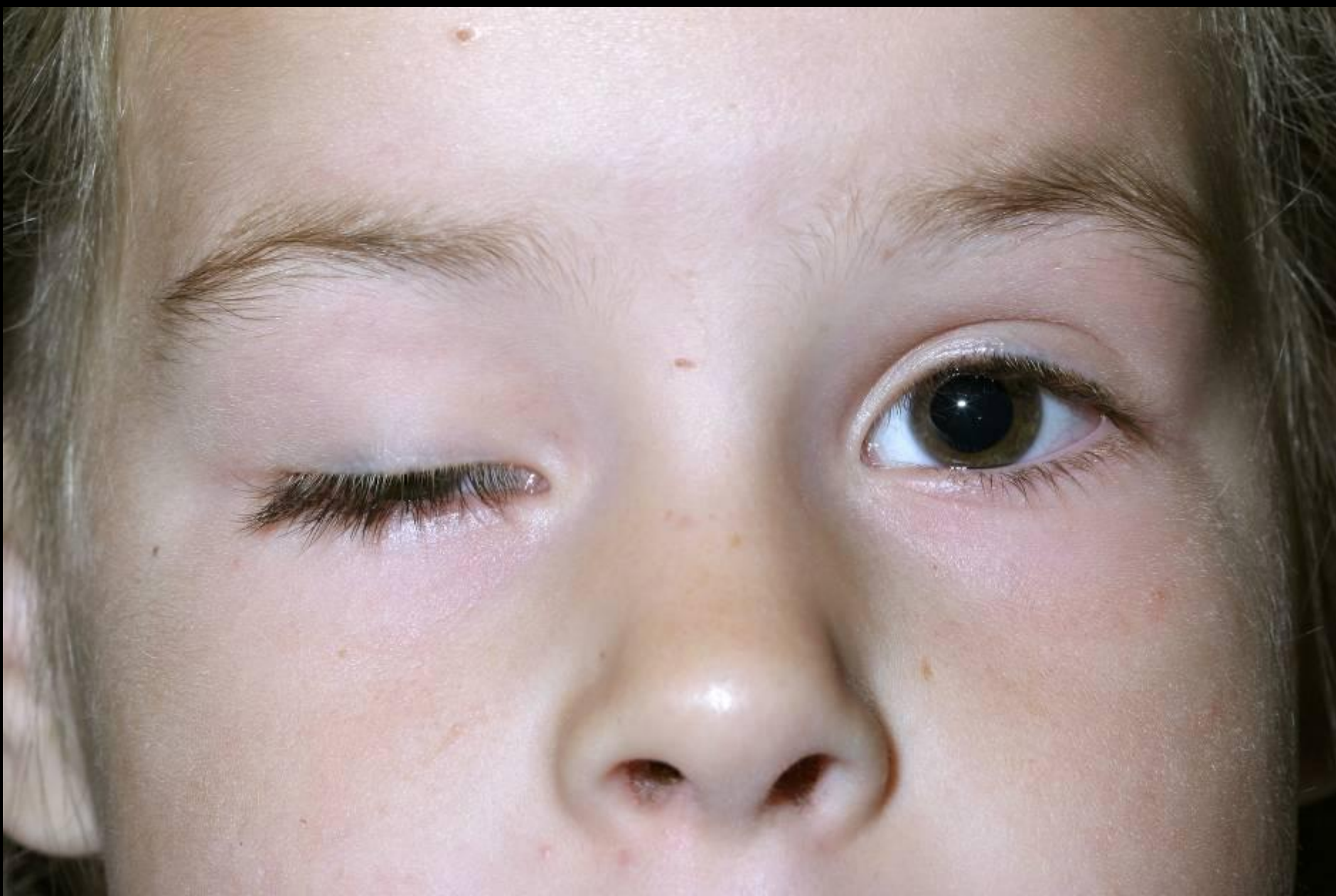panretinalis photocoagulatio proliferatív diabeteses retinopathiaban 77.



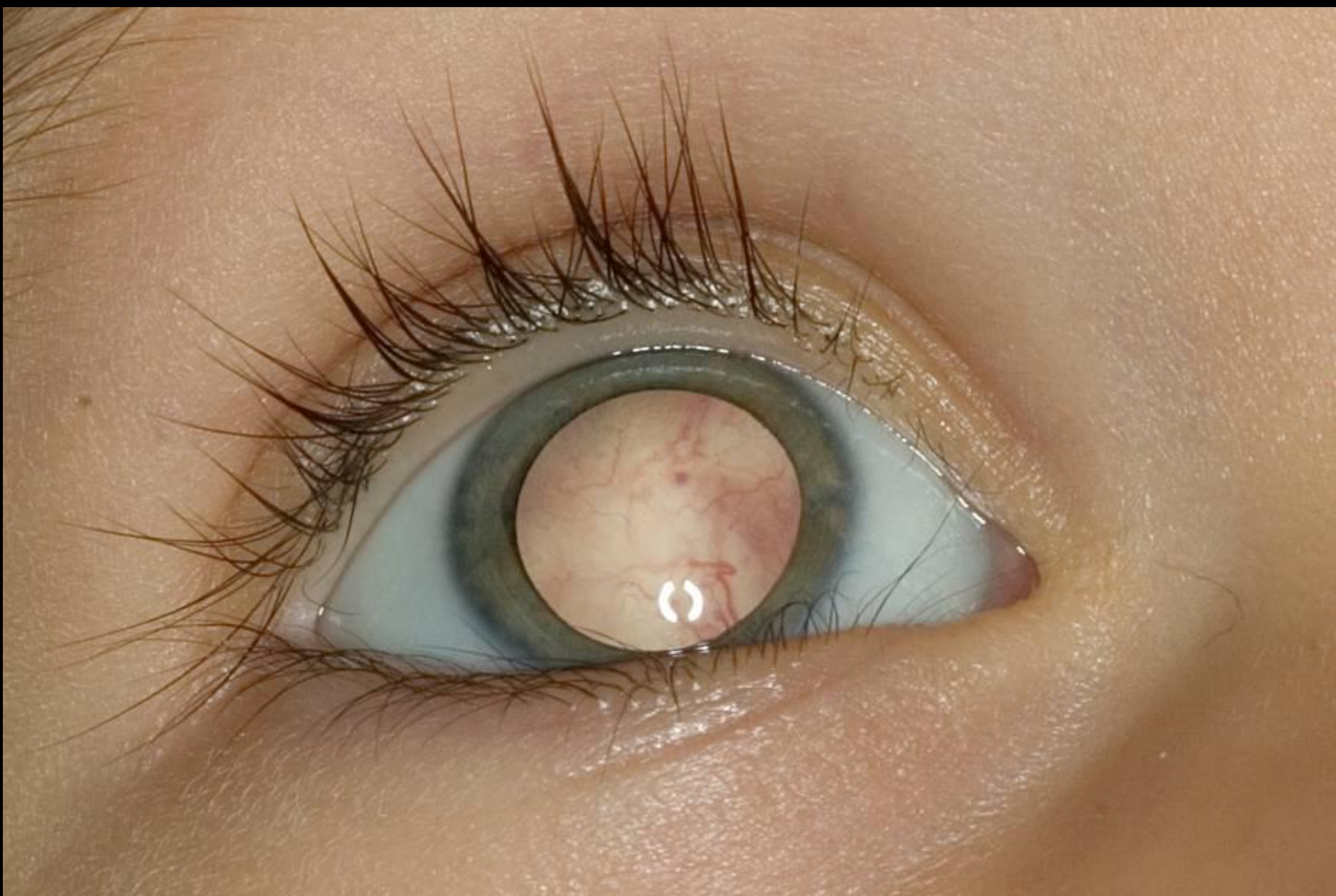phthisis bulbi



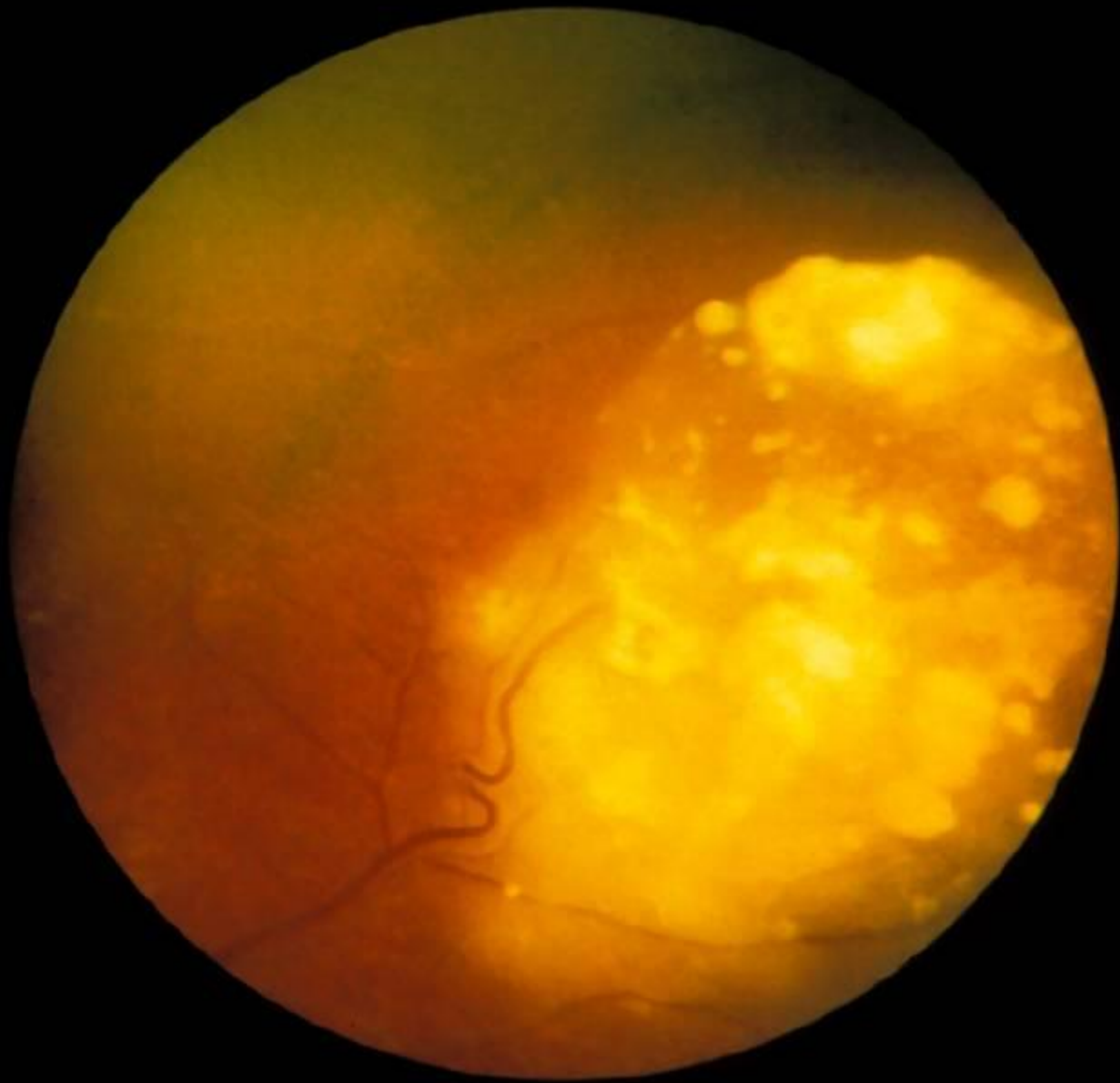
pterygium internum



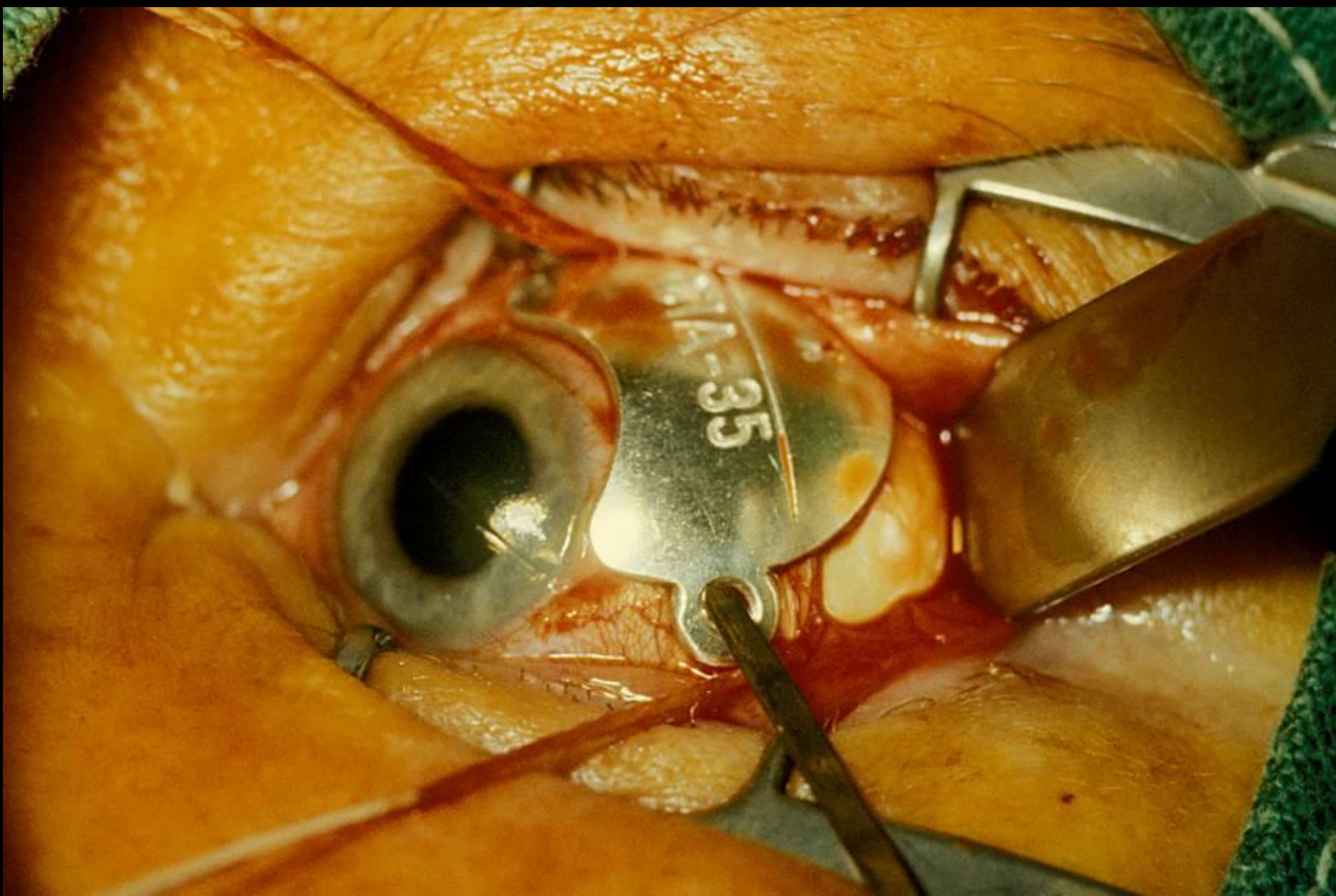
ptosis congenitalis totalis palpebrae



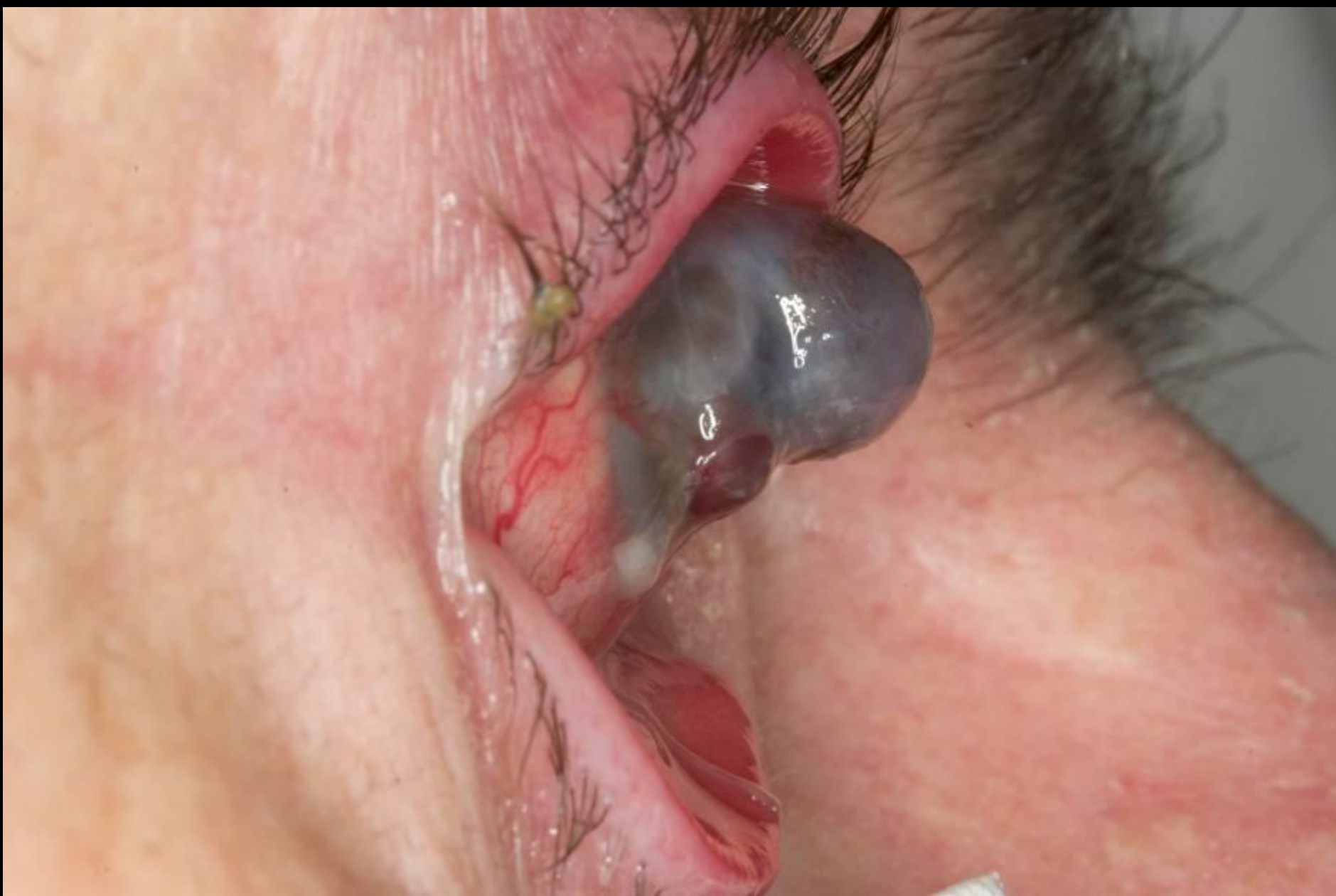leucocoria (retinoblastoma)



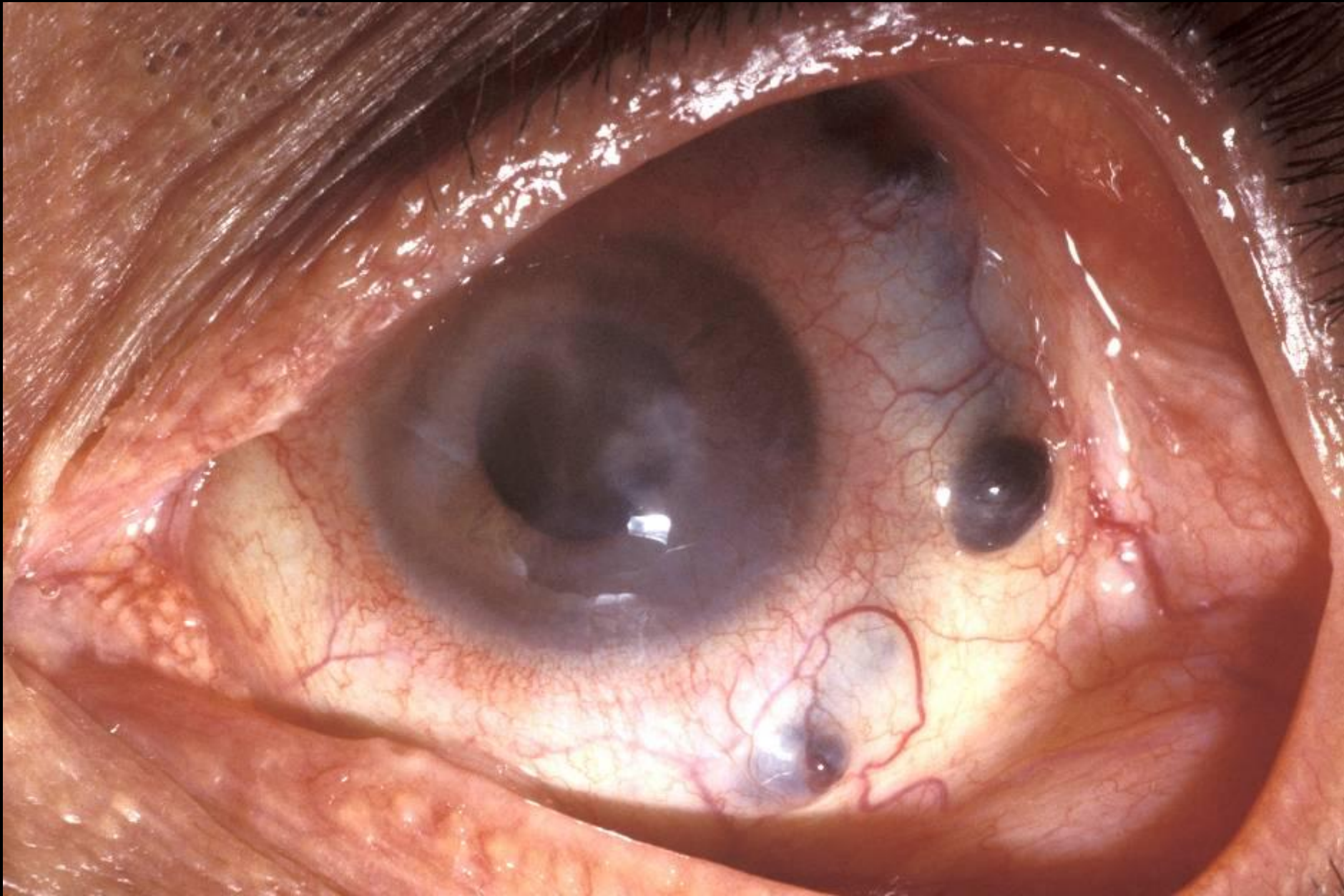
retinoblastoma



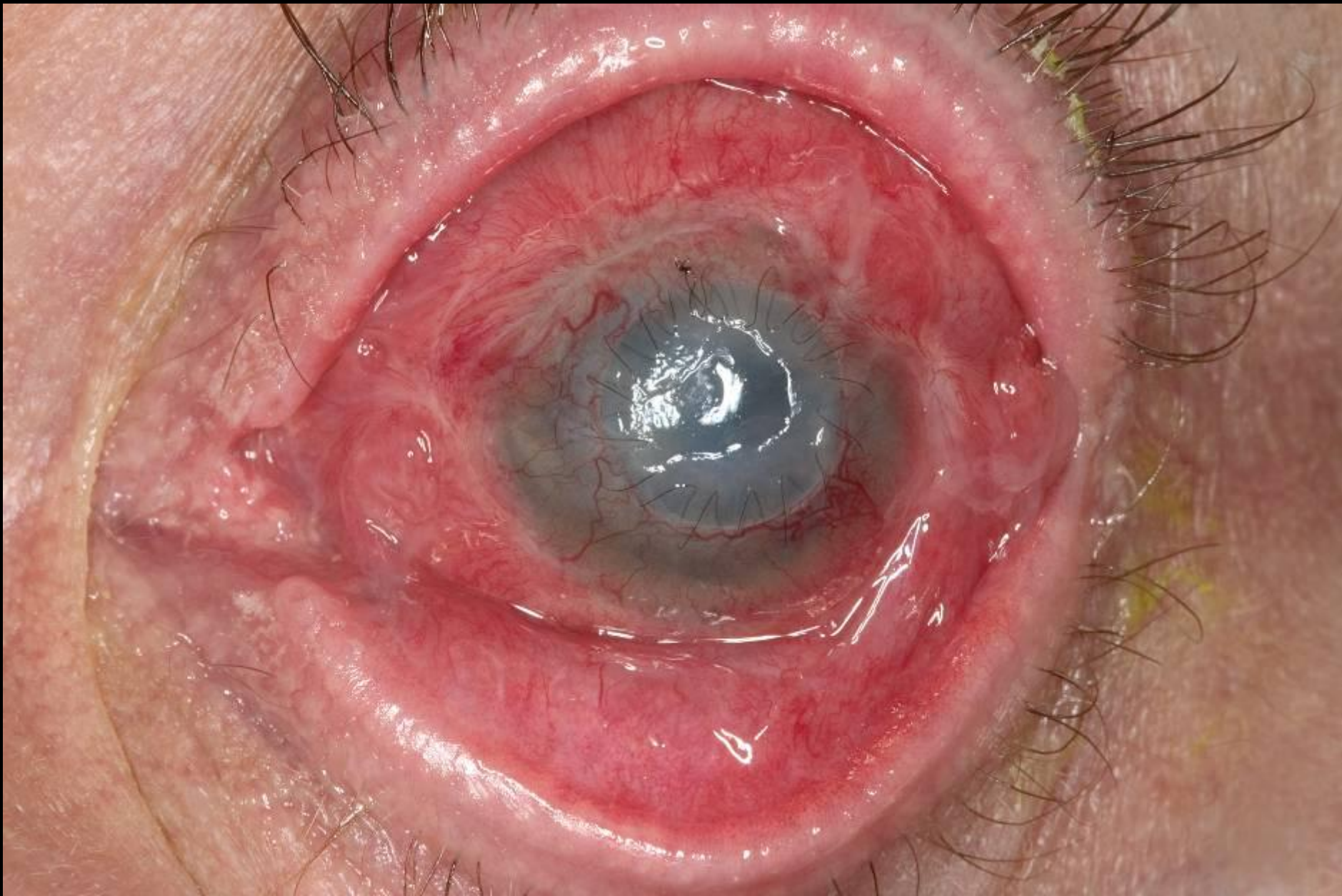Ru 106 contact applicator felvarrása



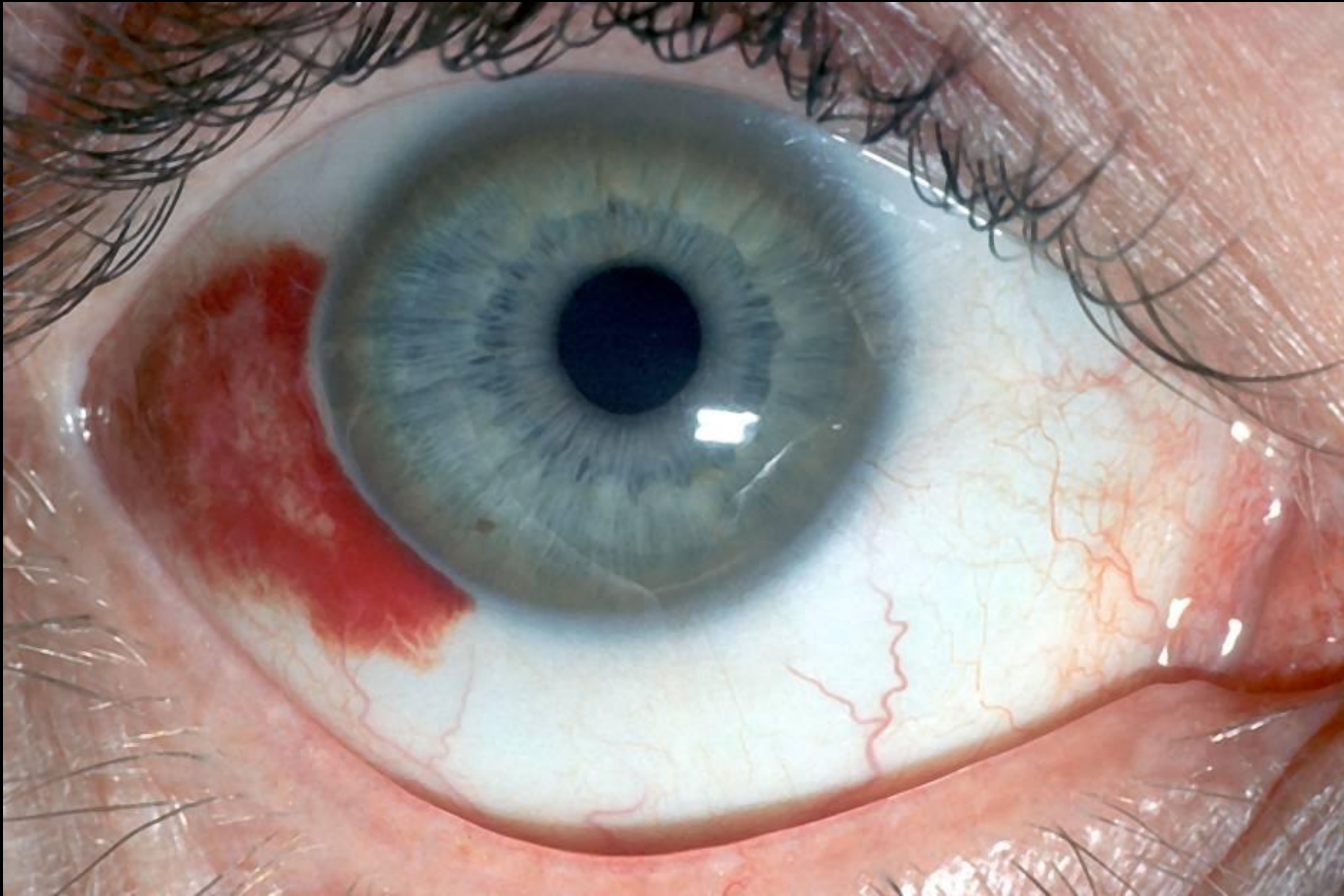staphyloma corneae



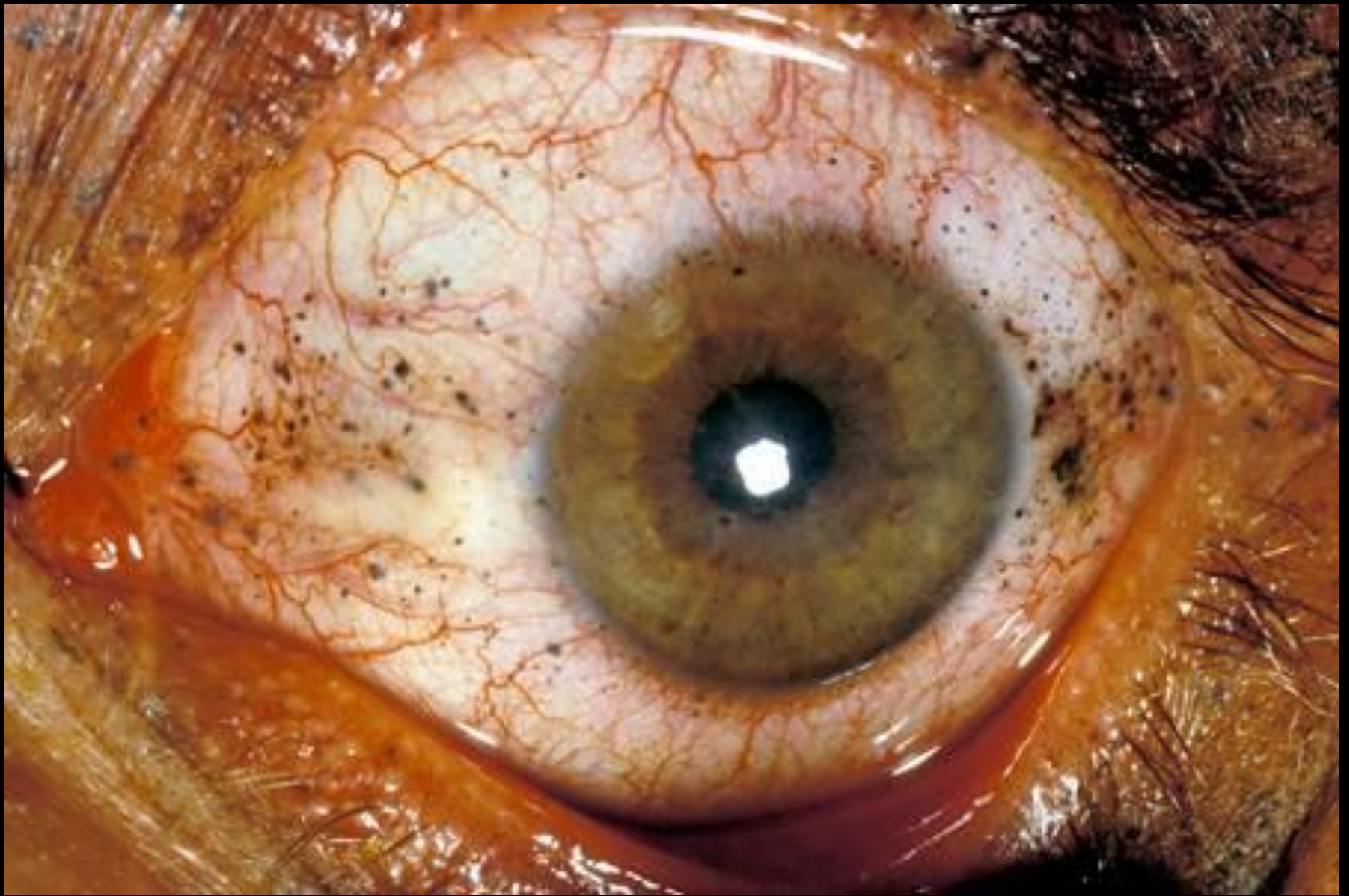staphyloma sclerae



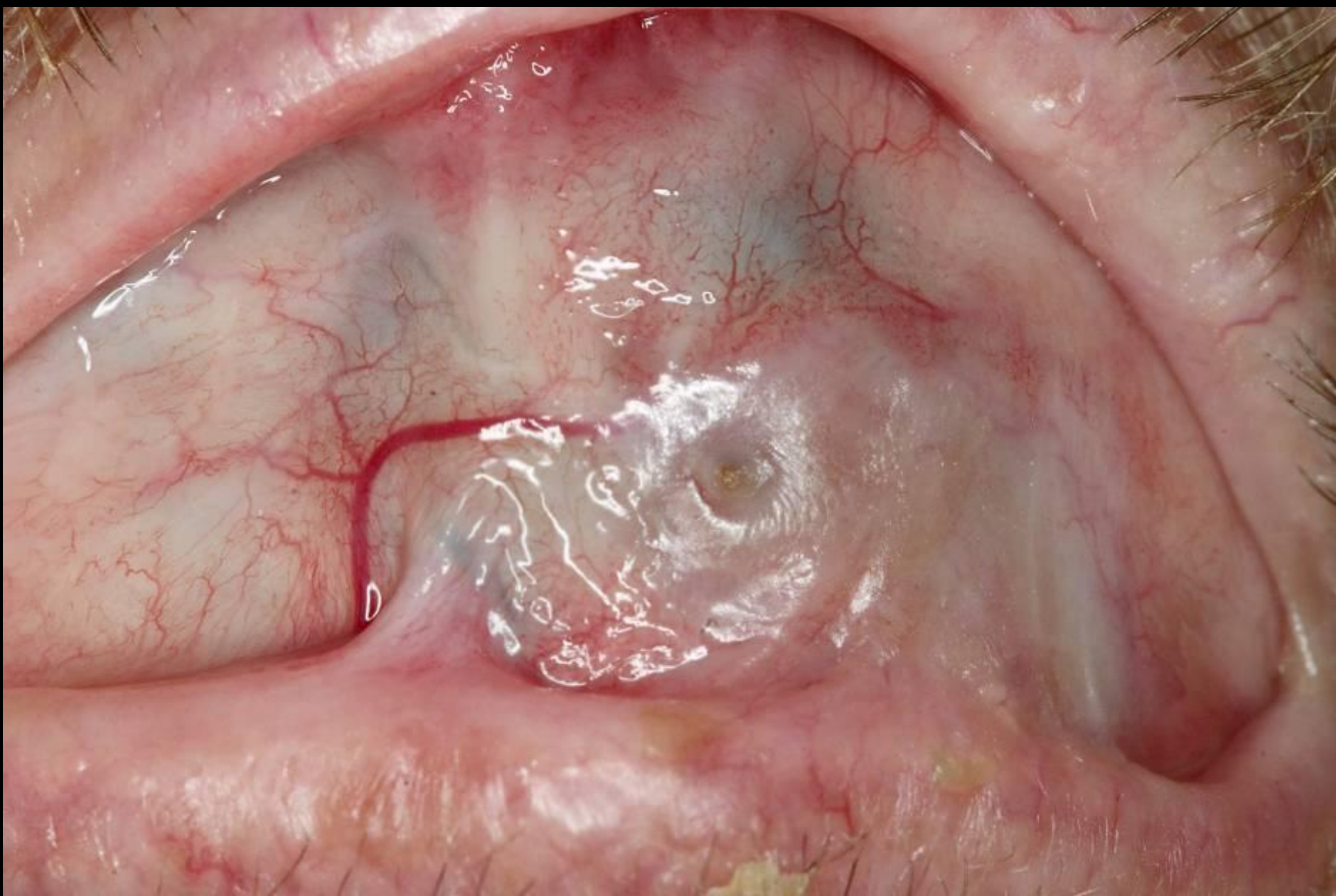
Steven- Johnson syndrome



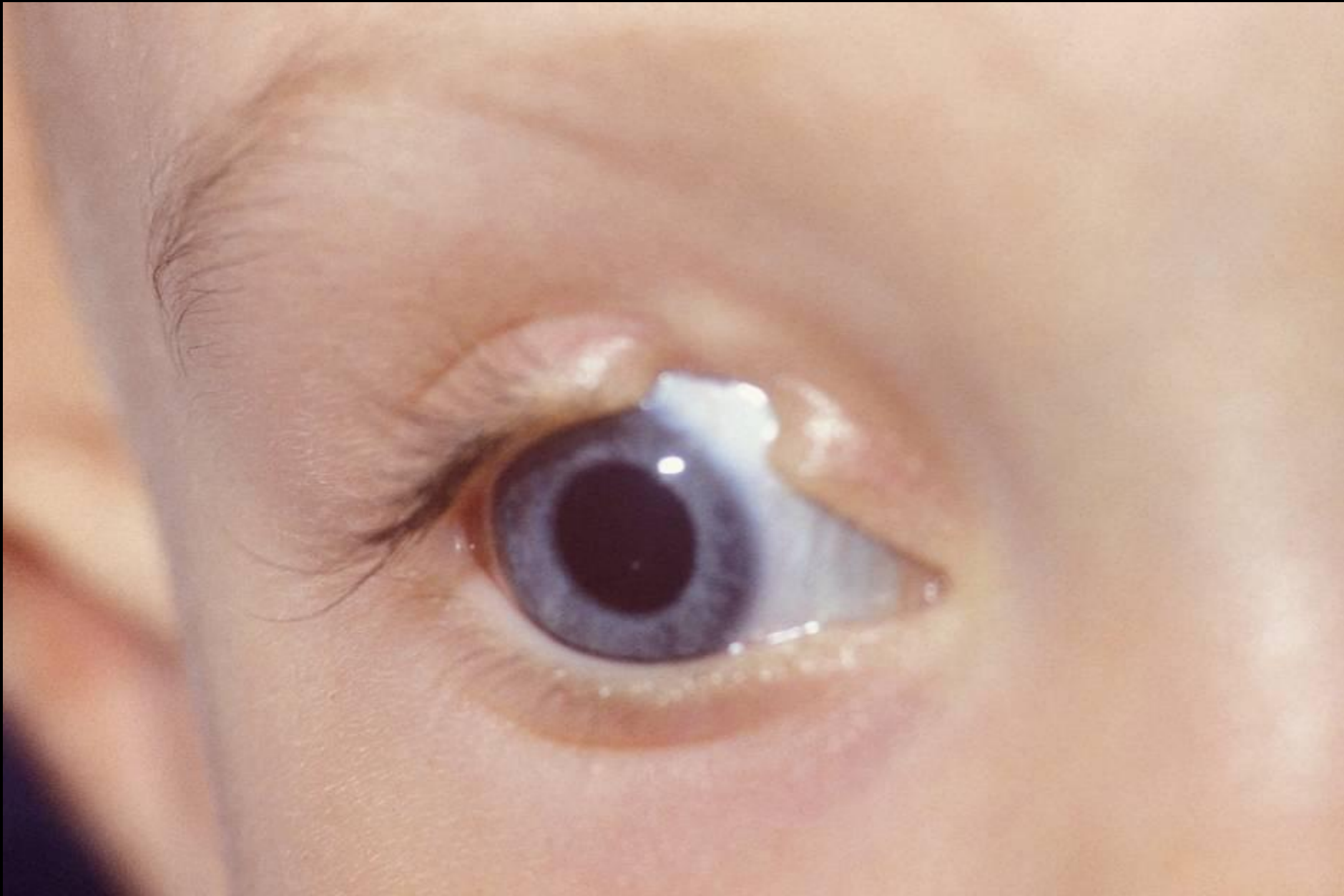suffusio subconjunctivalis



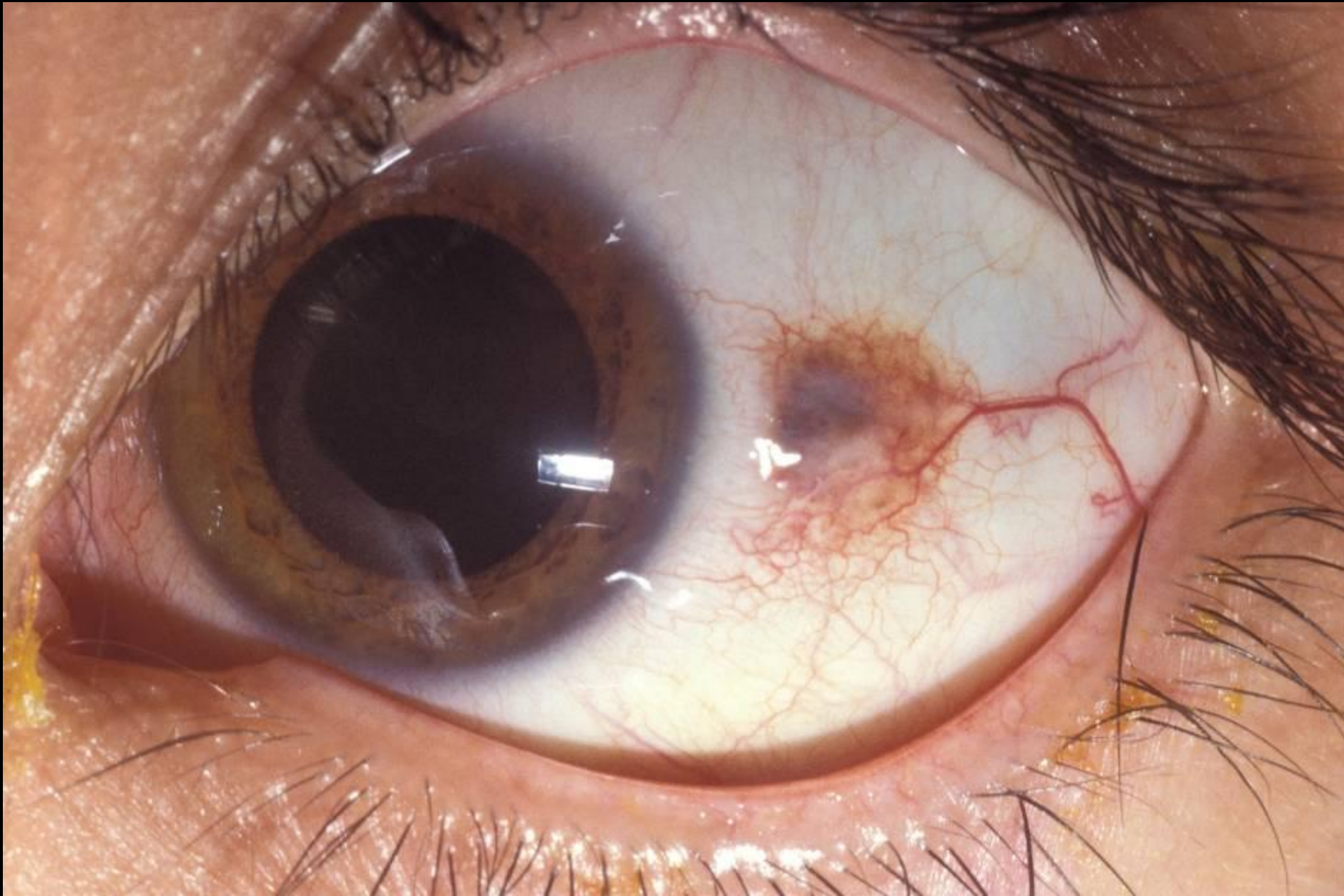
corporis alieni corneae et conjunctivae



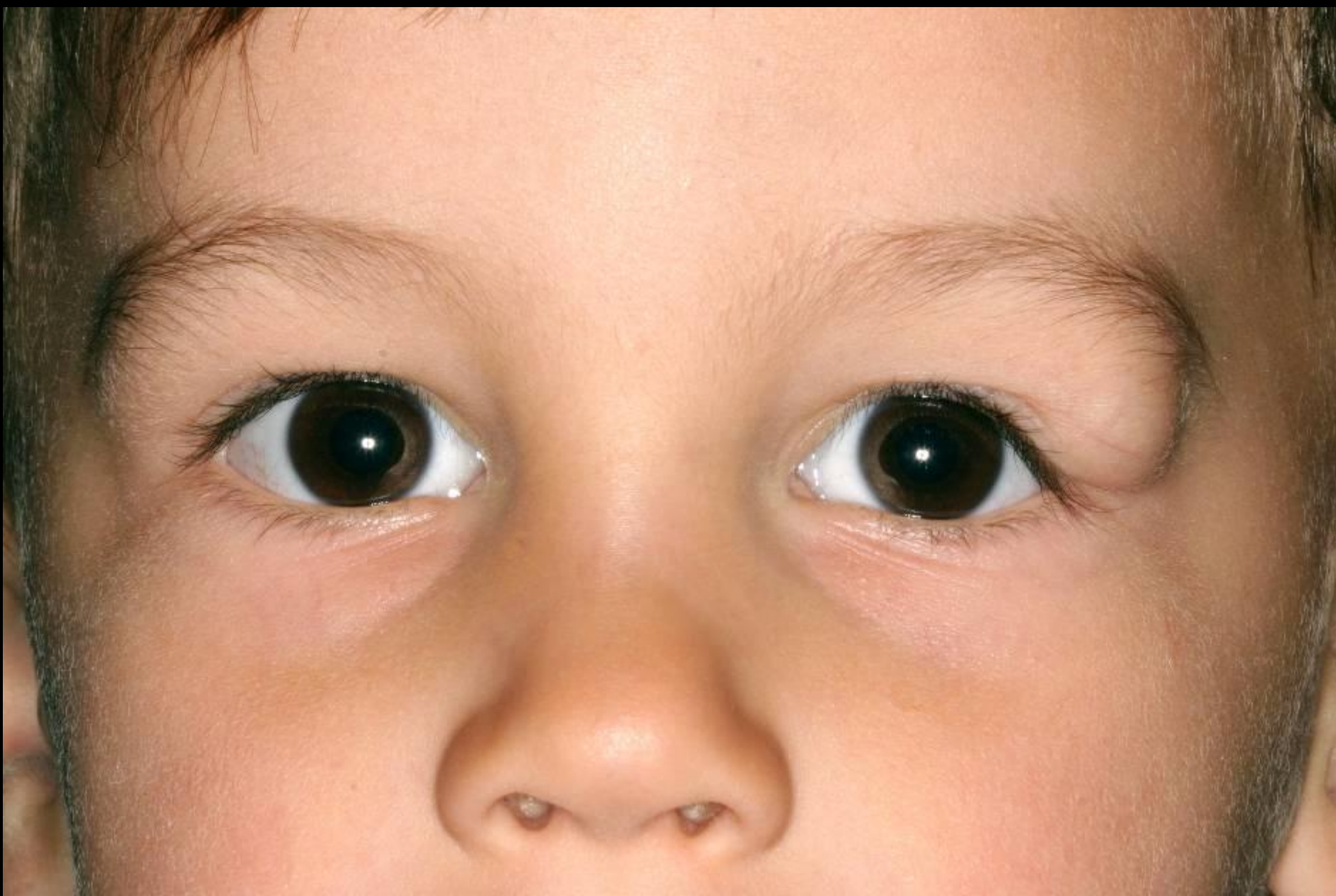symblepharon



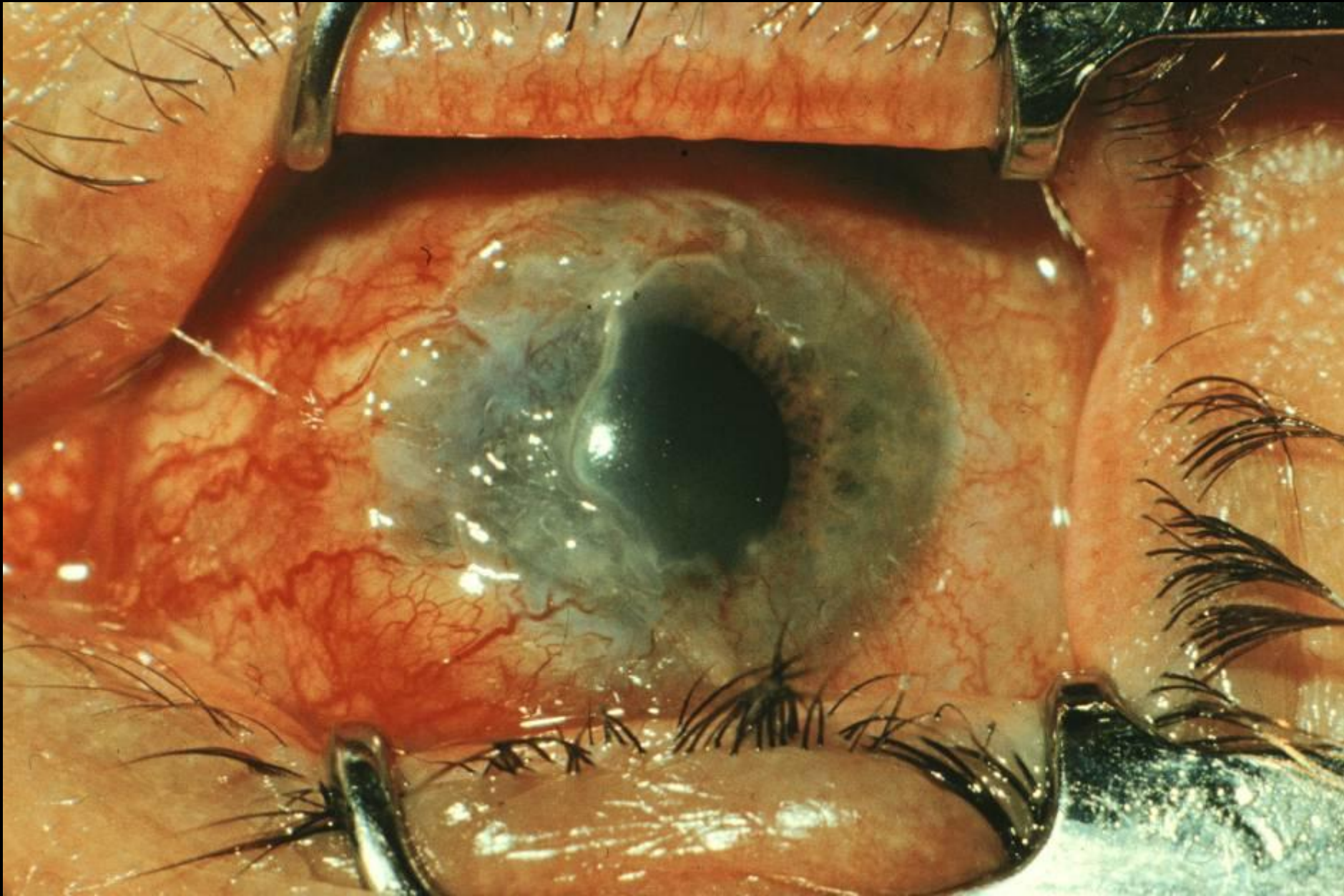
coloboma palpebrae superioris congenitalis



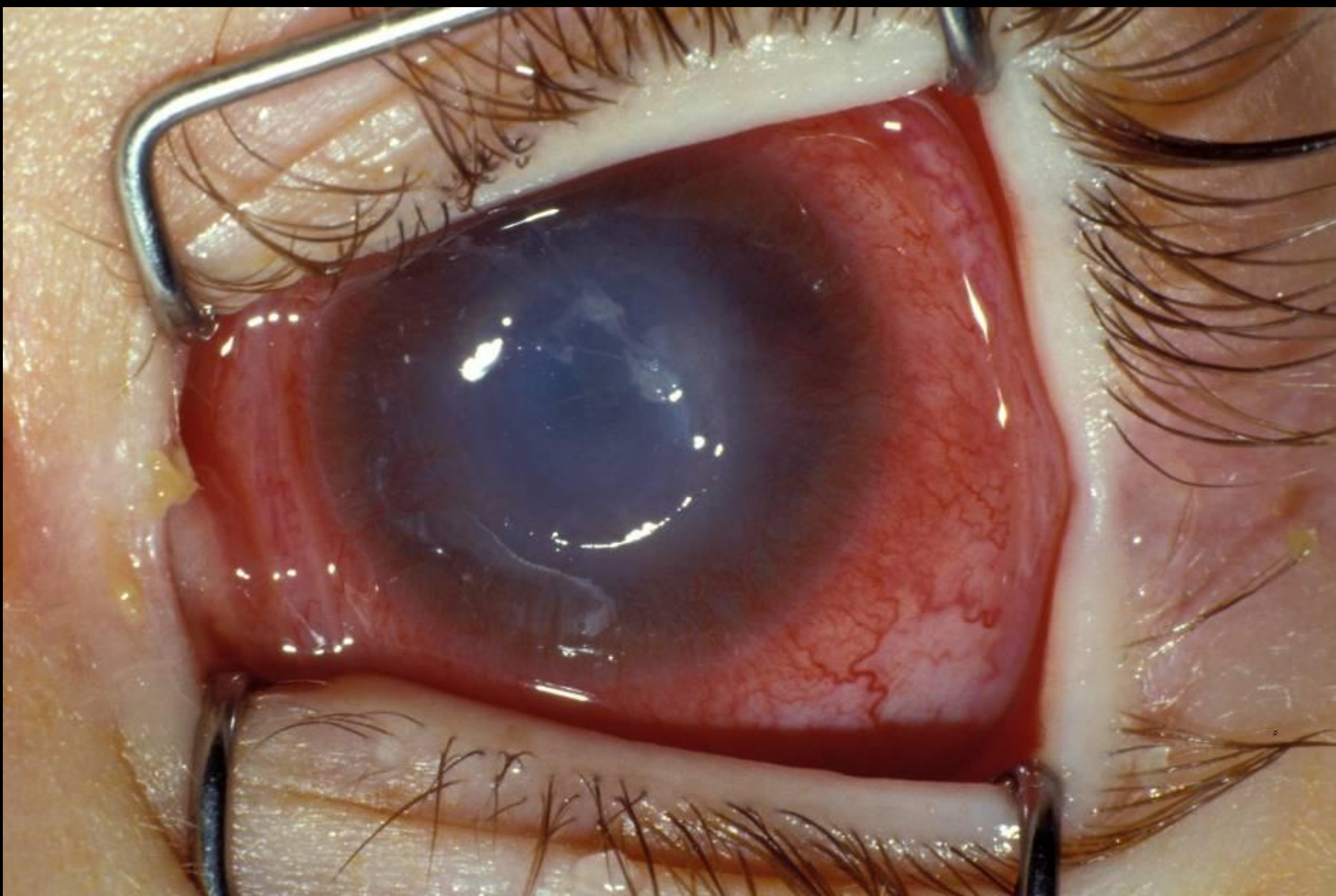
tumor conjunctivae



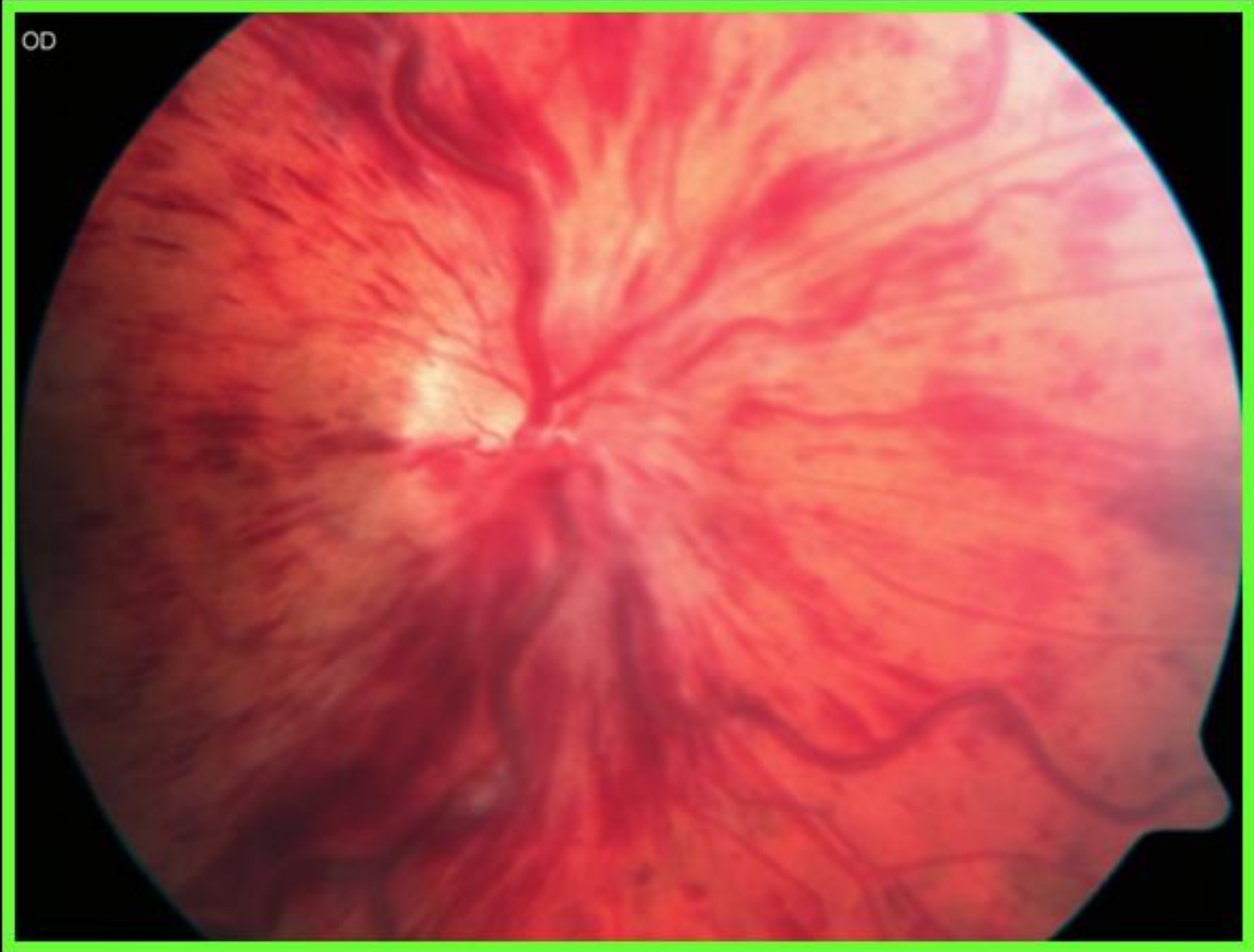
tumor orbitae



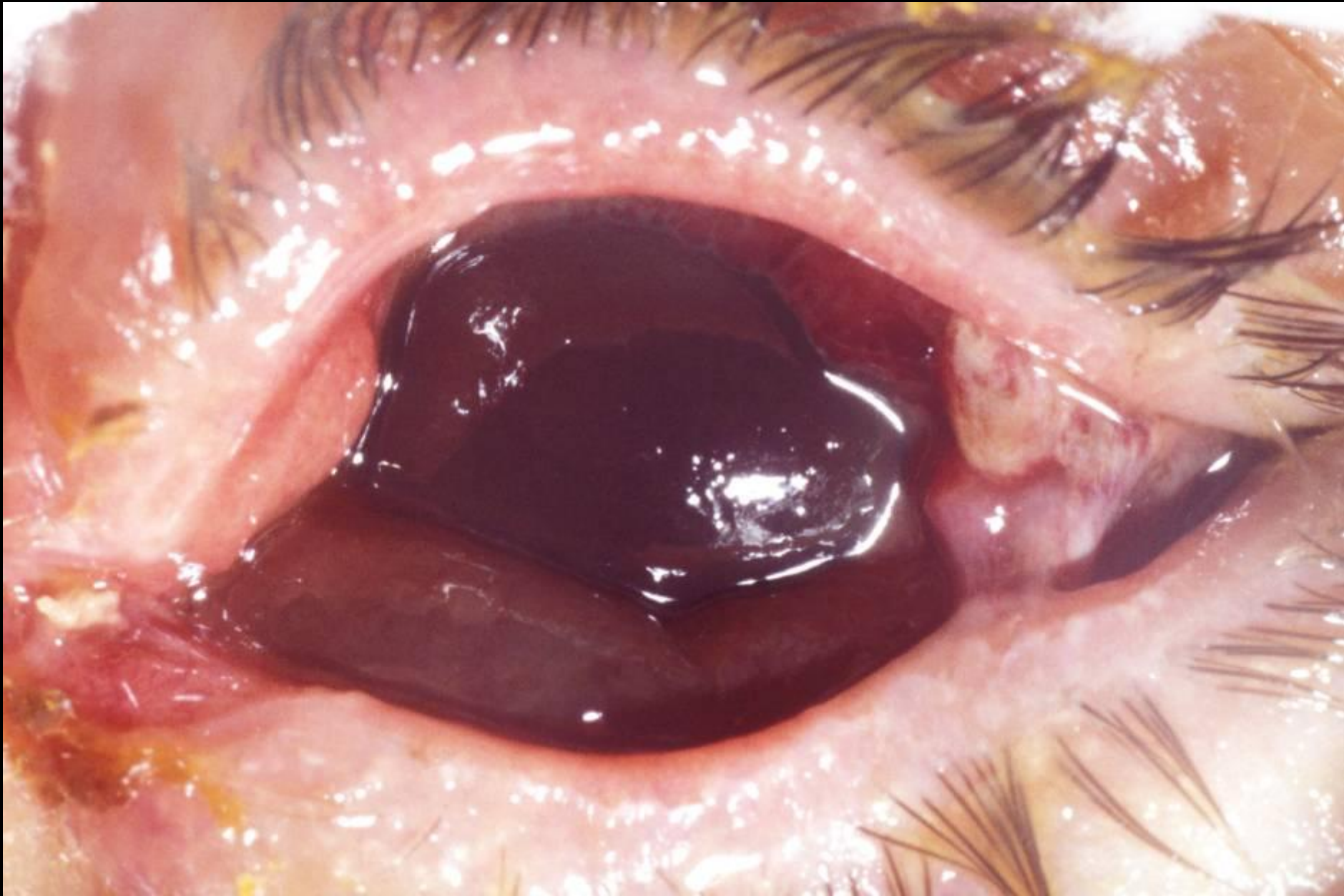
ulcus Mooren corneae



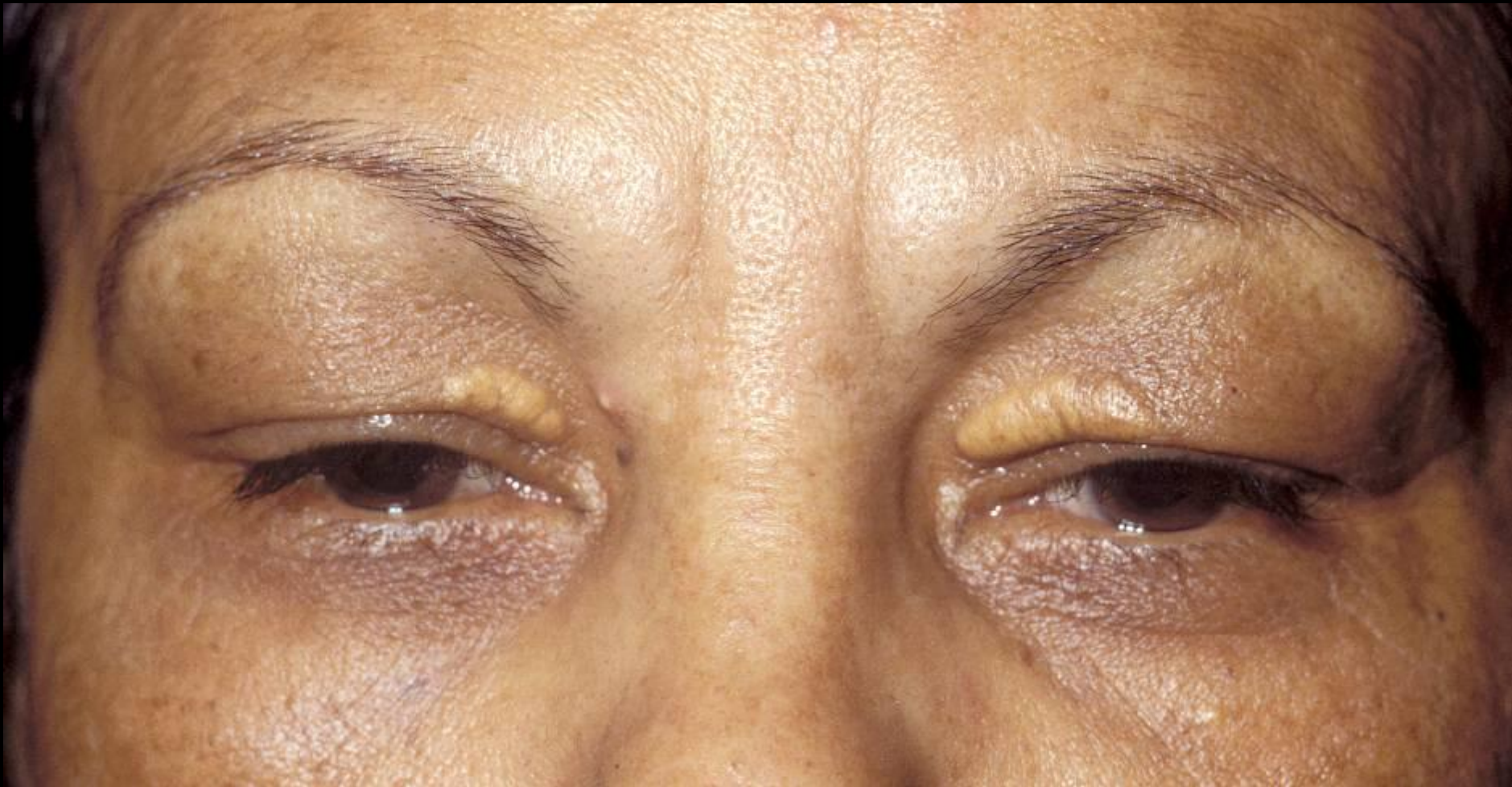ulcus bacterialis corneae



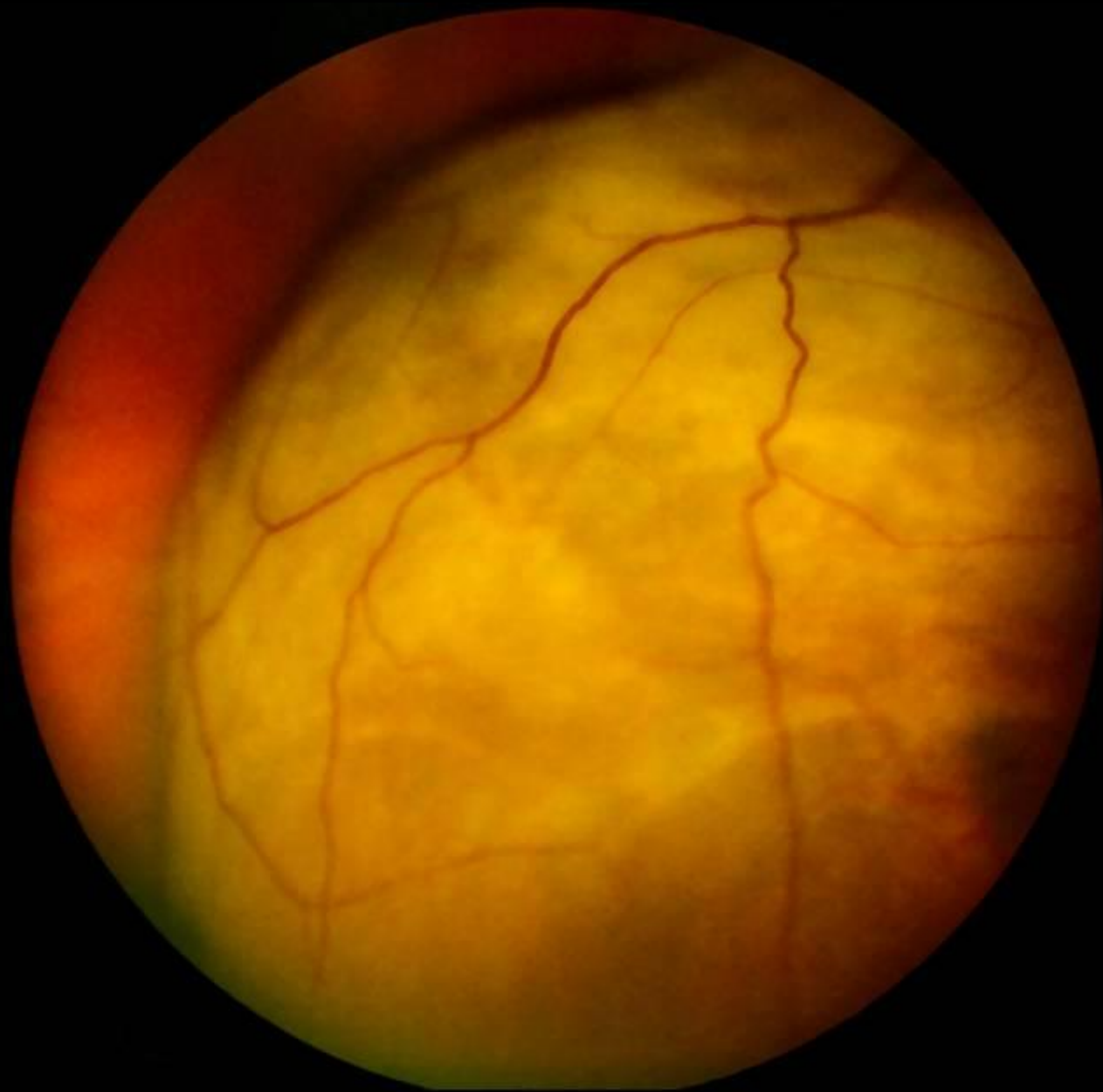thrombosis venae centralis retinae



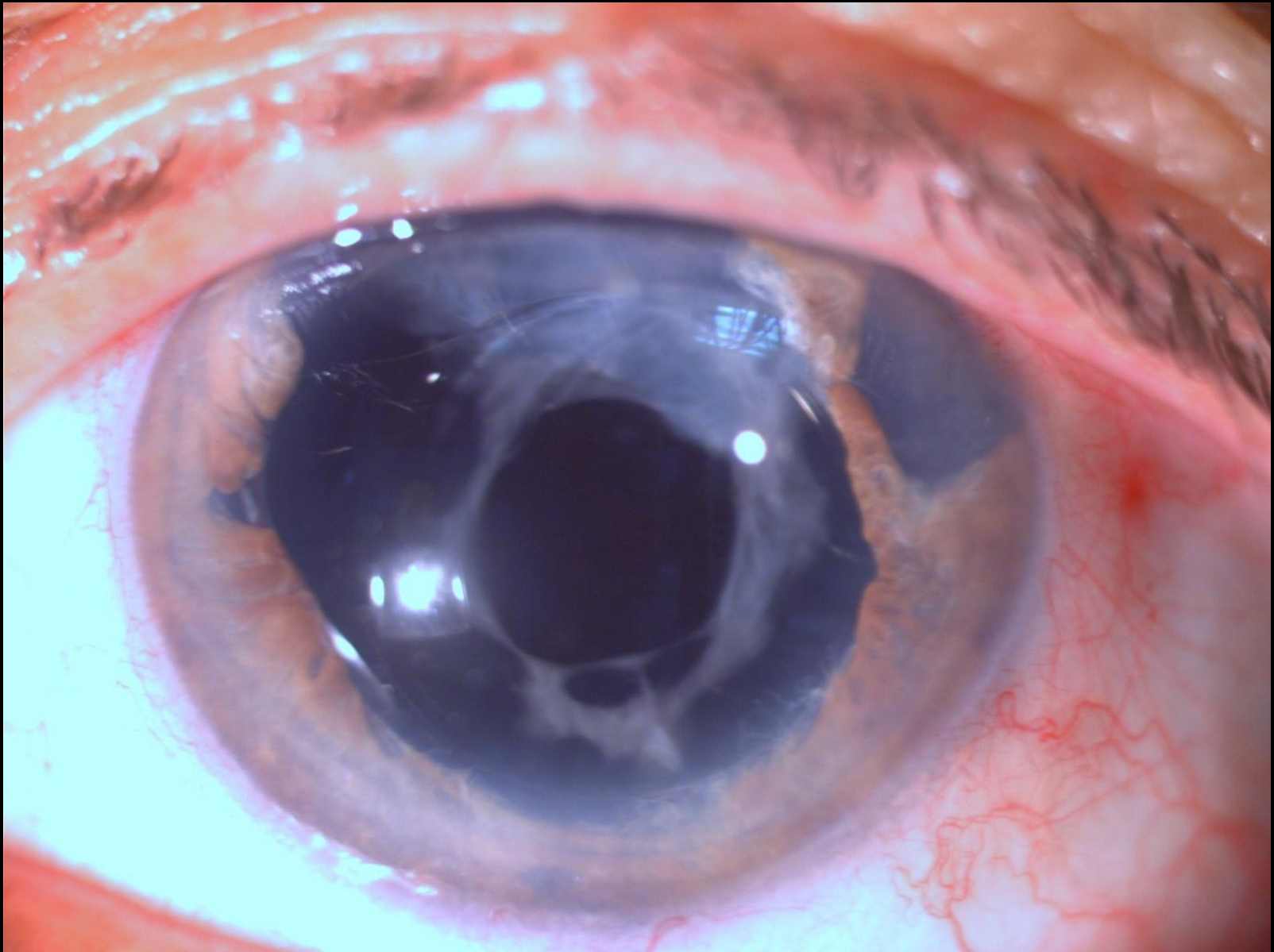
vulnus ruptum corneae et sclerae et collapsus bulbi



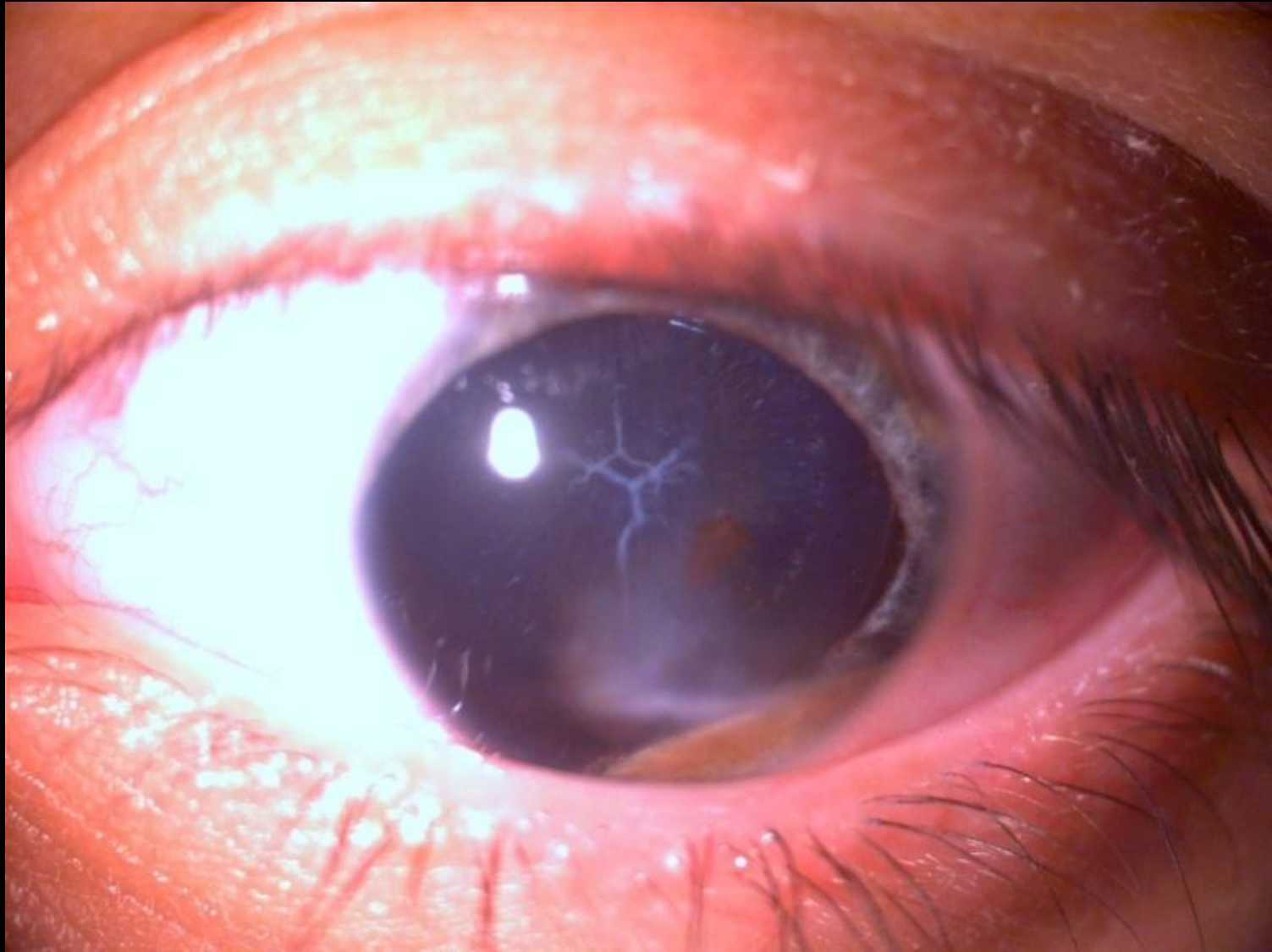
xanthelasma palpebrae superiores



melanoma malignum chorioideae



pseudophakia et cataracta secundaria et status post capsulotomiam 99.



mydriasis traumatica et cataracta partiale